

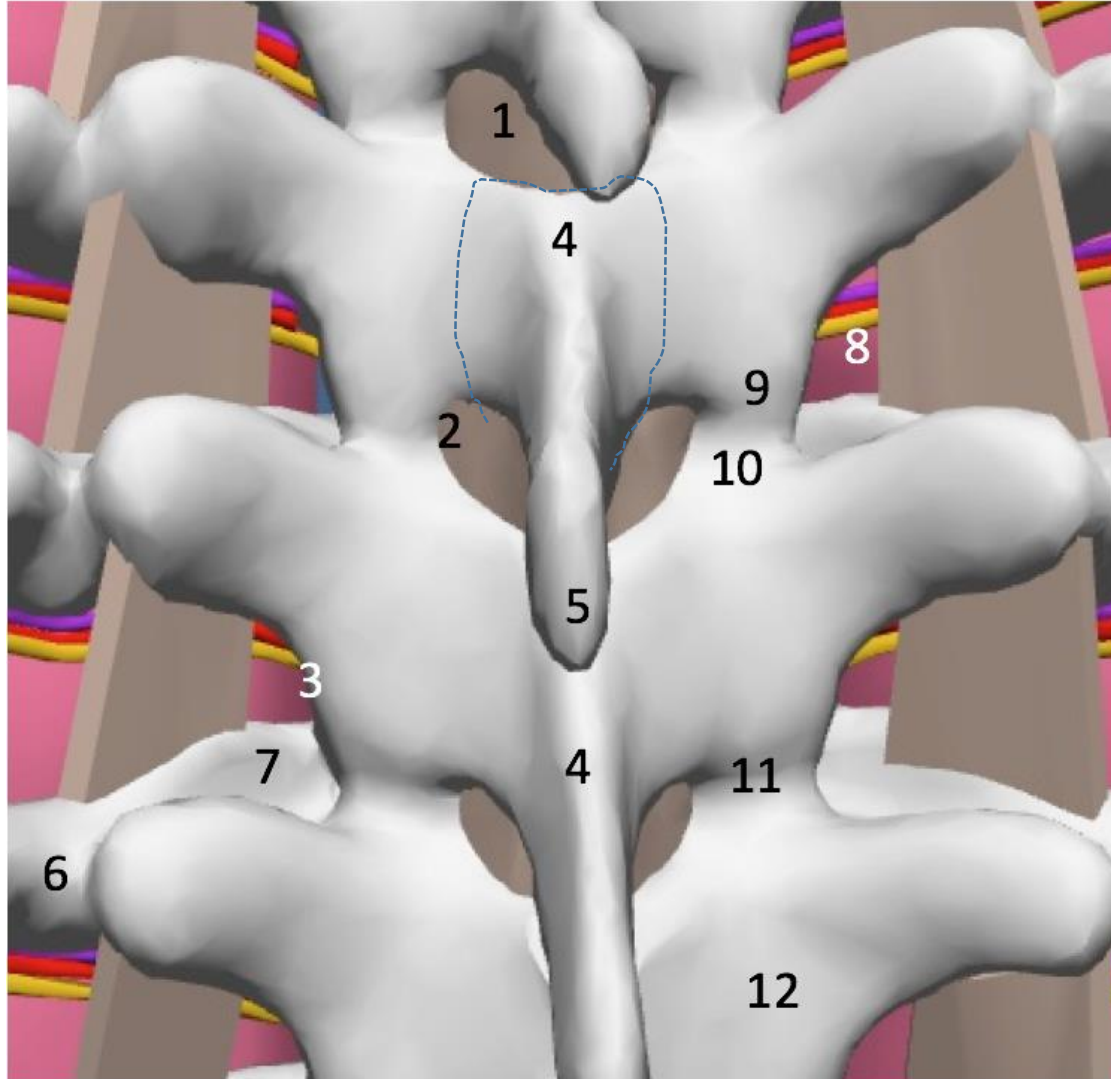
# Curriculum 2

## Lecture 2

Paramedian approach to mid thoracic epidural  
Landmark based technique (troubleshooting)  
and US assisted techniques  
Anatomy/sonoanatomy and procedures

TEC-thoracic epidural catheter, TEA-thoracic epidural anesthesia/analgesia

# So that we speak the same language, let us review of the basic anatomy again before moving on to cross sections and sono-anatomy



1. LF covering interlaminar space
2. Lateral edge of interlaminar space
3. Lateral edge of the lamina
4. Base of SP (dash line shows the outer border)
5. Tip of SP
6. Proximal part of the neck of the rib
7. Head of the rib
8. Medial TPVS
9. Inferior articular process (IAP) of the facet joint
10. Superior articular process (SAP)
11. Facet joint line
12. mid lamina

# Basic 3D anatomy to jump start vertebrae cross-sections literacy

## Thoracic vertebrae between T4-T9 as a unit

To facilitate understanding of the cross sectional anatomy, we can divide the area into 3 zones

**A-zone (midline).** The following structures are located in this zone:


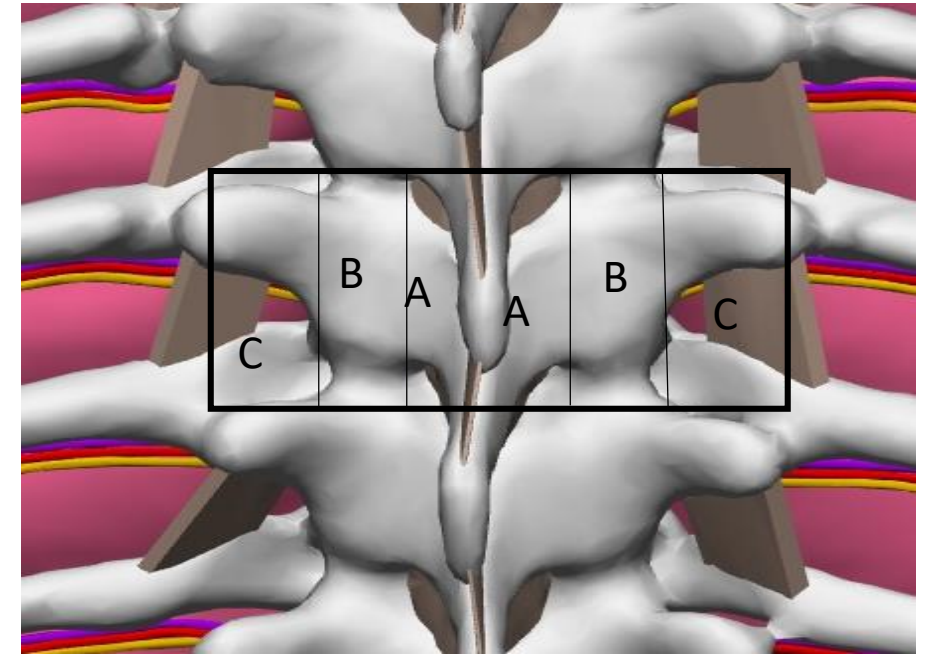
base of SP plus tip of SP of vertebrae above , interlaminar space

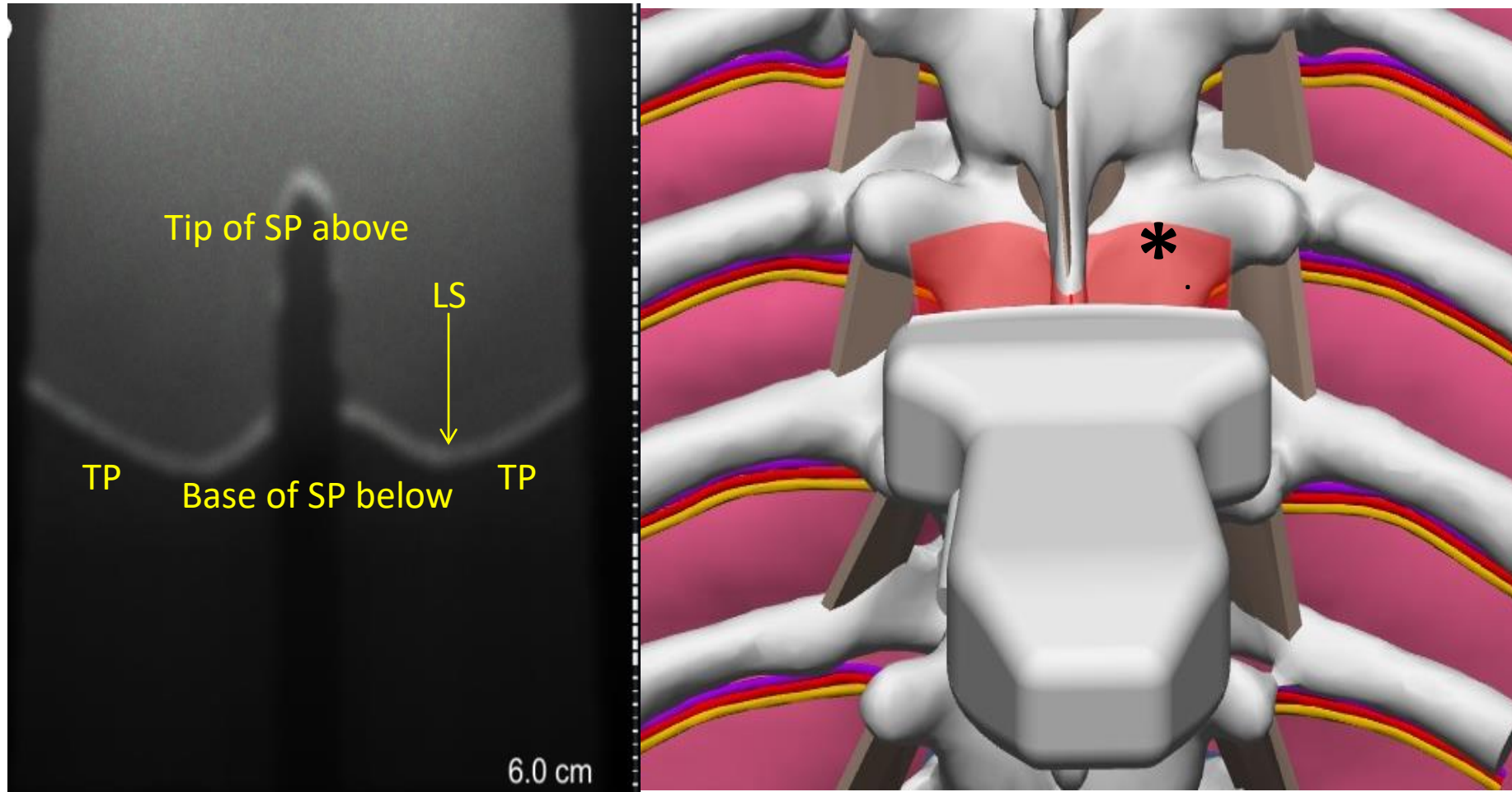
**C –zone (lateral).** The following structures are in this zone: TPs and heads of opposed ribs.

**B- zone.** Laminae and facets are in this zone. We usually land our needle in between zone A and B or in the medial part of zone B for the paramedian approach

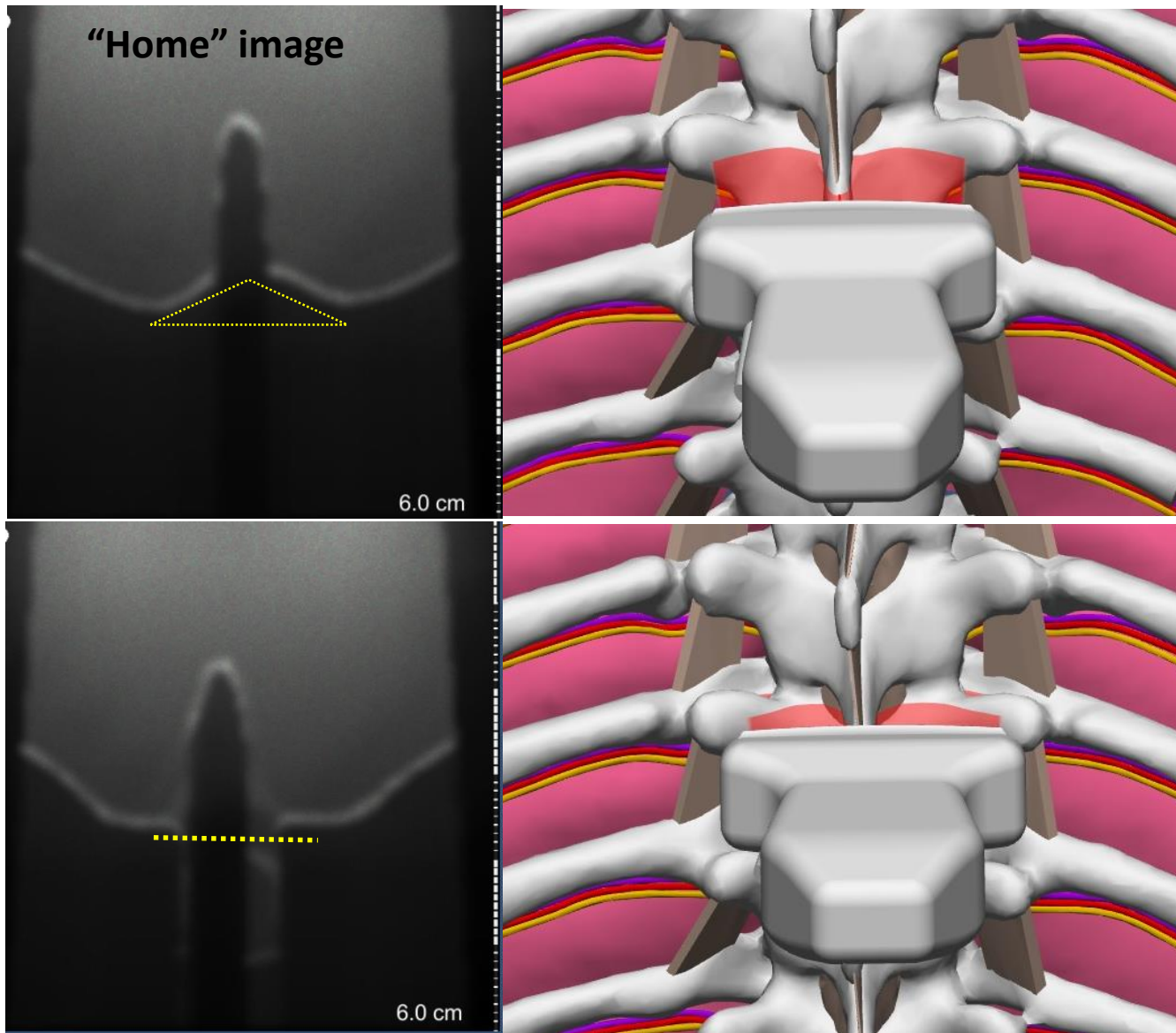
One should examine the cross-sectional anatomy, paying attention to differences in zones A,B, and C . Difference includes different shapes and depth from skin (see the cm markings on the right side of the ultrasound image)

We will use a virtual US beam and virtual US images in conjunction with 3D illustration of the anatomy to teach basic ultrasound cross-sectional anatomy of the thoracic spine to guide you in using needle palpation and ultrasound techniques for T-epidural performance



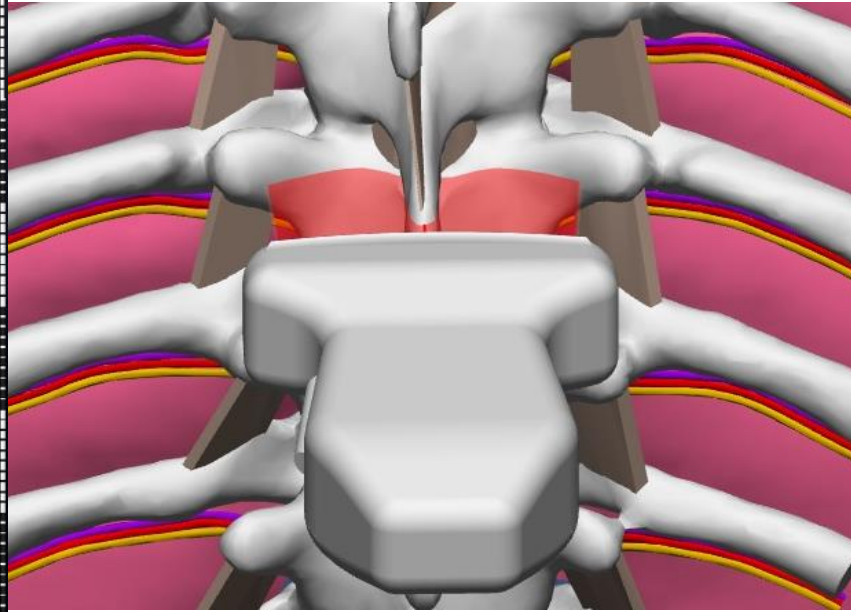
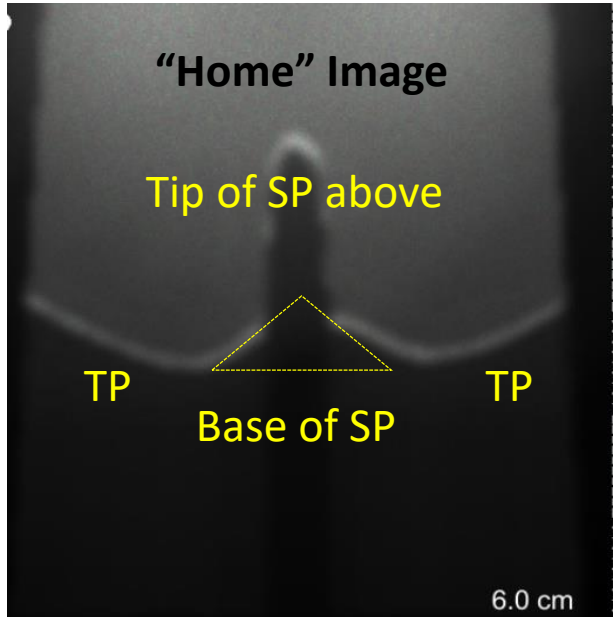


LS is the landing spot on the initial needle pass (About 1cm lateral from midline and about 1-1.5 cm caudad from the facet joint line). As you walk medially (~5-8mm) you should feel a step up. Then, walk up vertically into the interlaminar space at about the same distance.

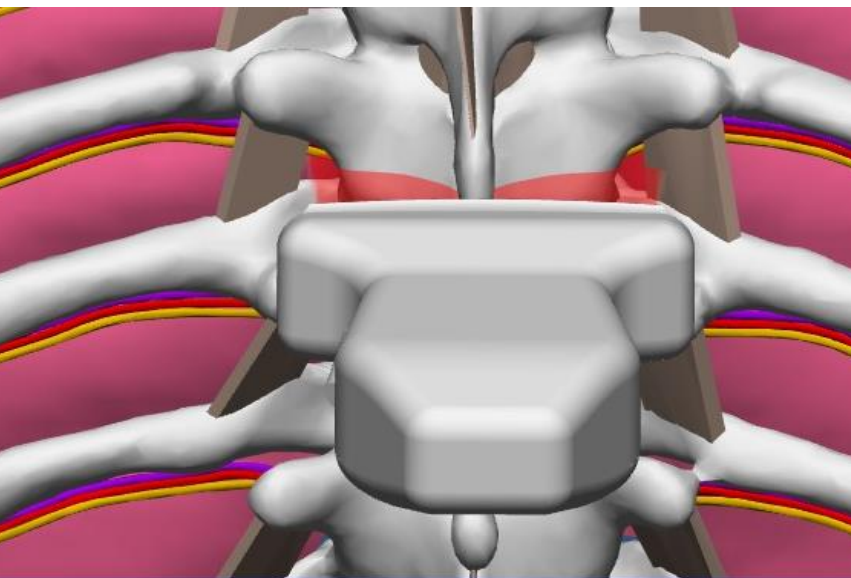
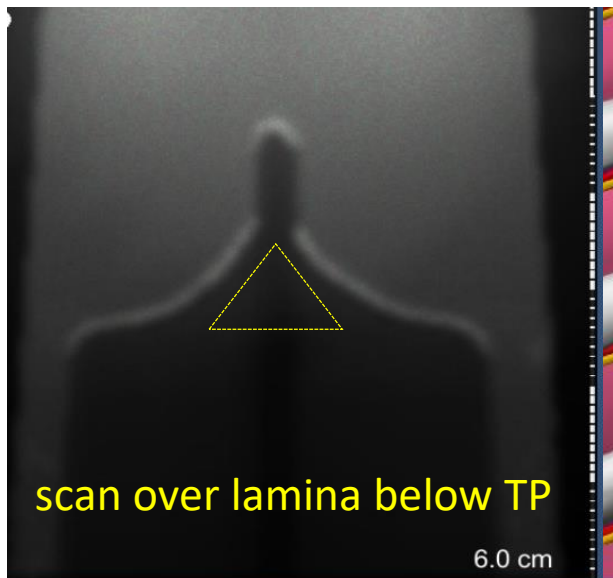


If the needle lands more cephalad at the level of SAP (bottom cross section image) you will not appreciate a step up during a medial walk and may feel a drop into the interlaminar space.

# Expected needle palpation when we land more caudad than the ideal LS



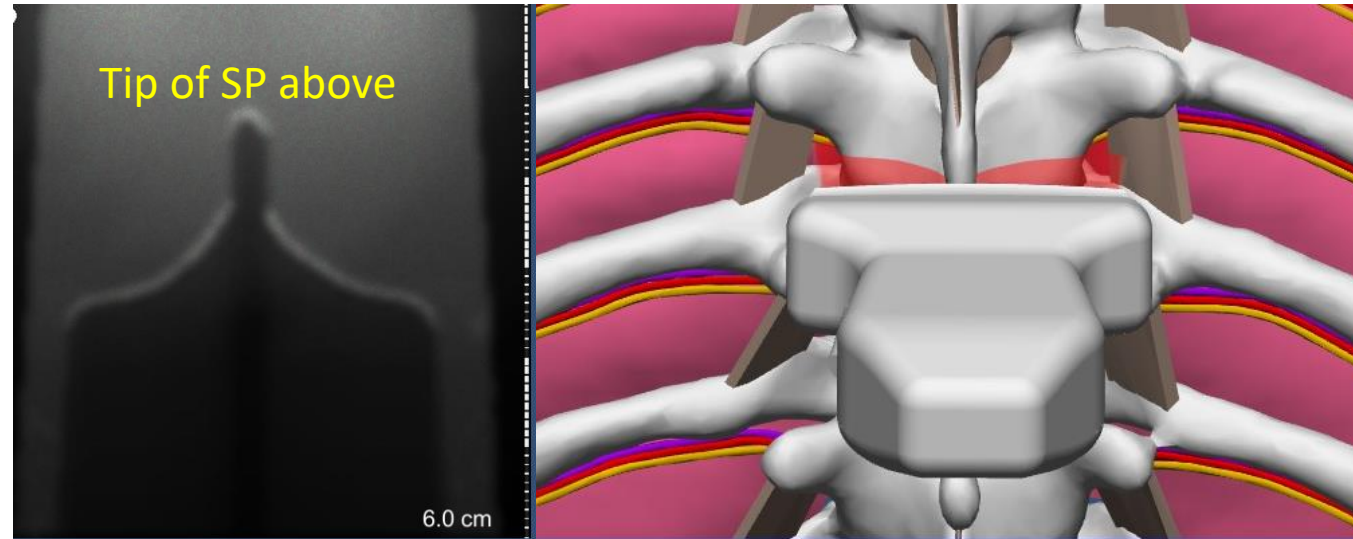
If the needle lands more caudad (bottom image) than the ideal LS ("home image"), you will feel a much steeper step up during a medial walk. During the vertical walk you will walk a longer distance before sliding into interlaminar space.



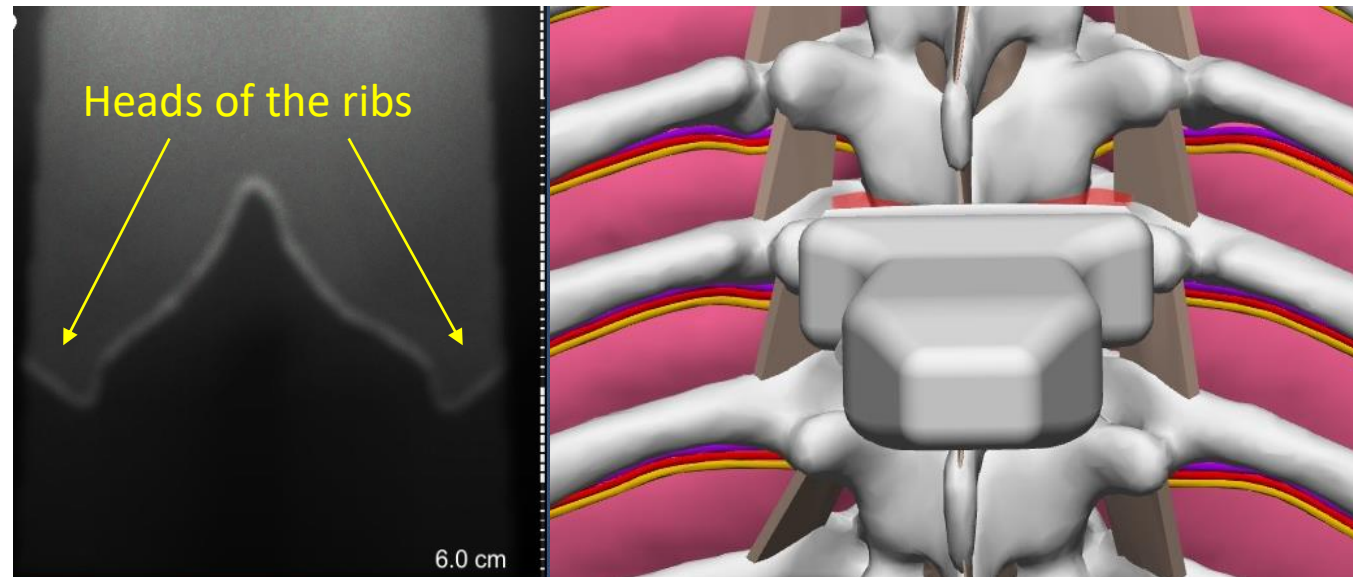
\*If you decide to walk laterally, you will not appreciate a step up because there is no TP there. After additional lateral step needle may fall into TPVS.

# Landing needle even more caudad


If the needle lands even more caudad( bottom image) than the previous example (upper image), you will feel an even steeper step up during a medial walk. During the vertical walk you will walk an even longer distance.



\*If you decide to walk laterally, you will feel a drop and feel the head of the rib.



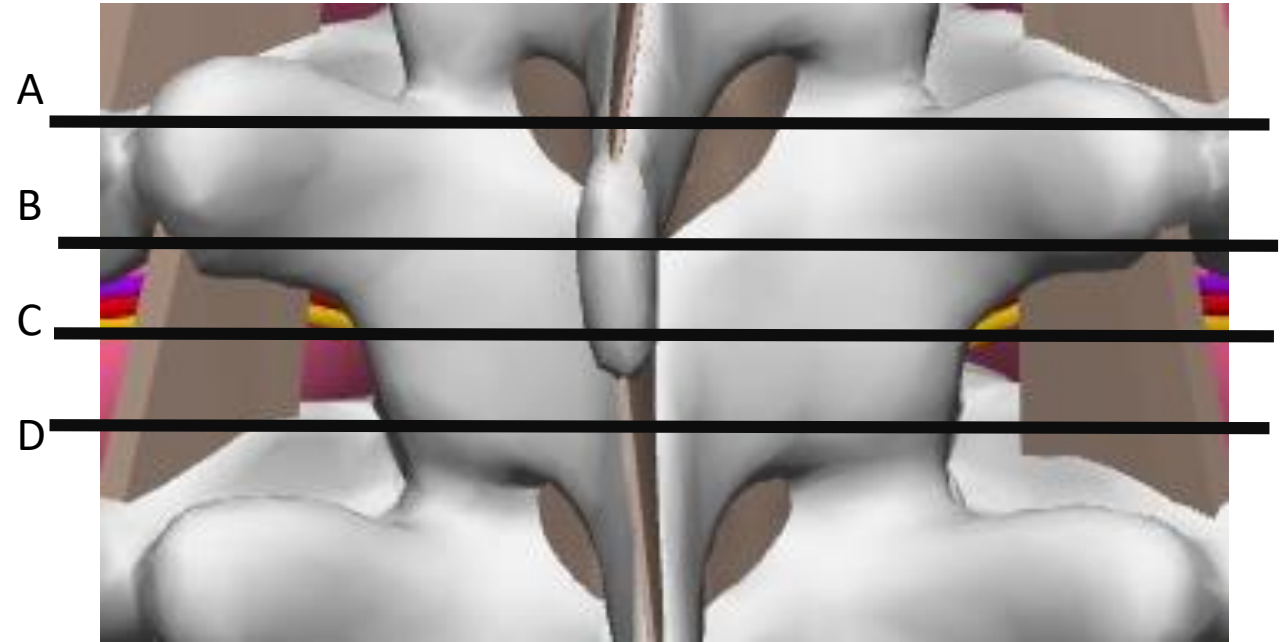
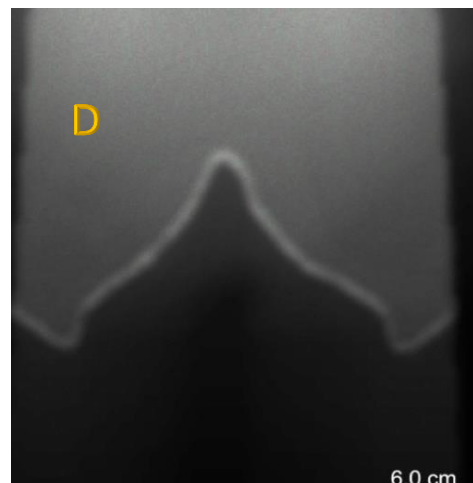
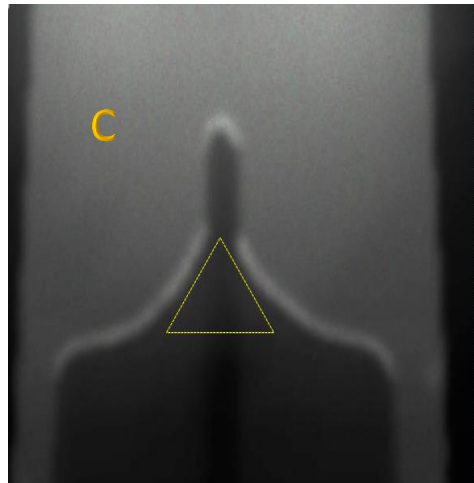
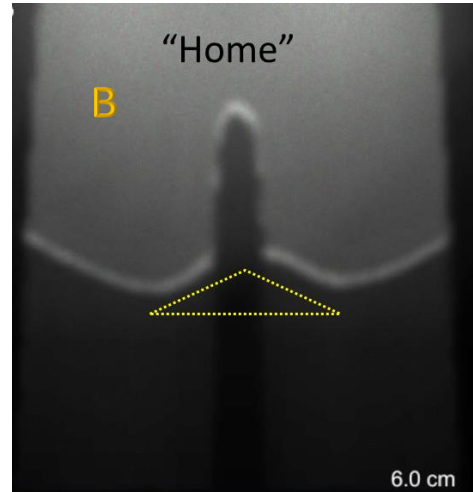
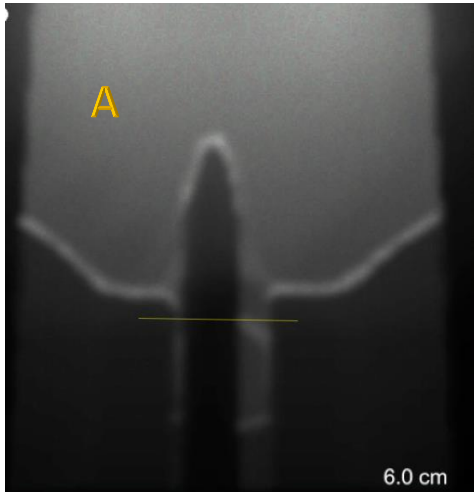
Occasional cross section when we will see elements of 3 vertebrae in one image



We call it the “Namaste sign”



## Main axial cross-sections/US view of thoracic vertebrae summary



- A upper edge of TPs lower edge of SAP
- B lower edge of TPs –midlamina
- C lower lamina below TPs above heads of the ribs,
- D IAP level and level of heads of the ribs

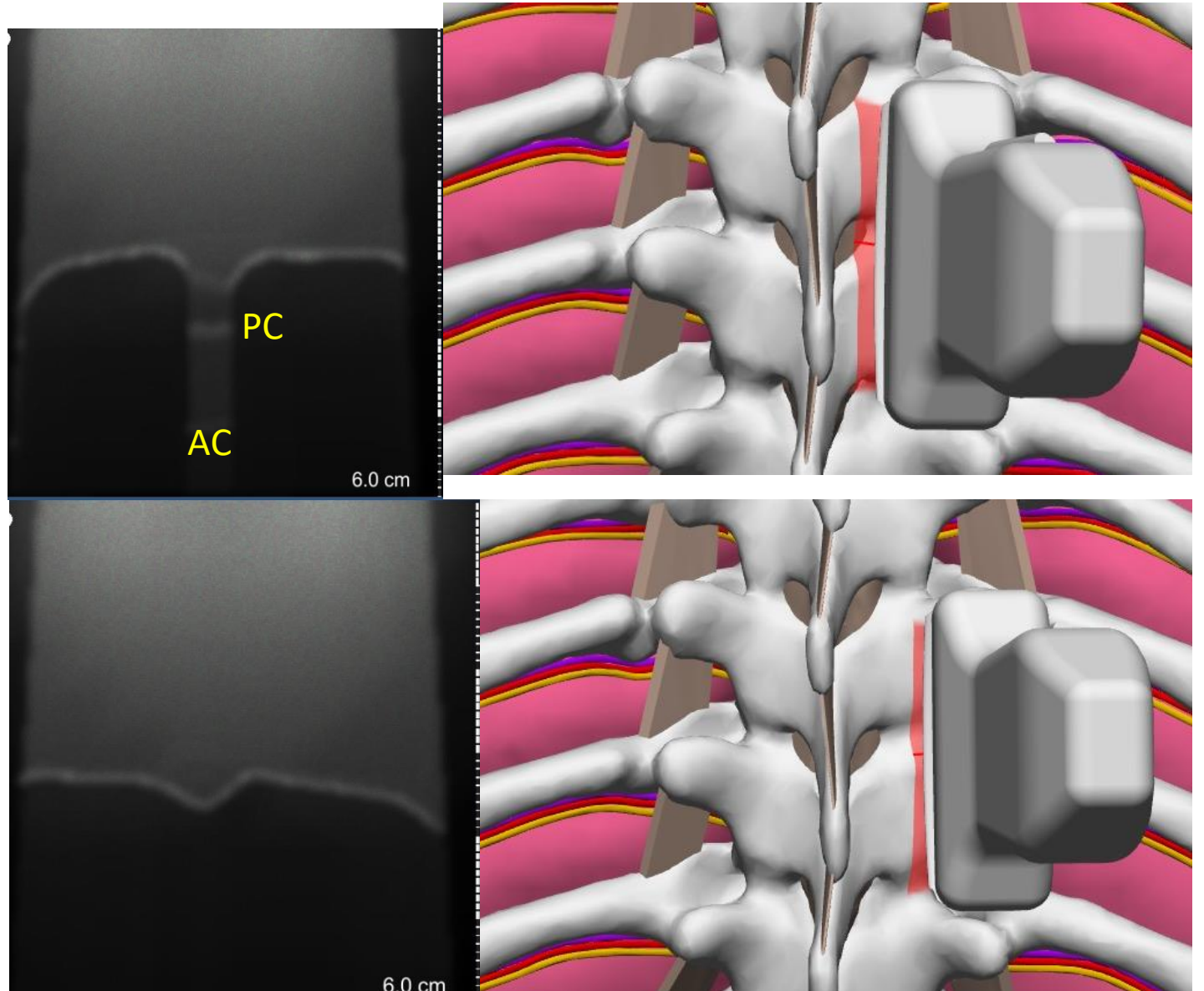
As you walk your needle tip in baby steps medially or occasionally laterally you may deduce its location based on the feedback on the bony depth profile after several steps ( “staying flat or climbing up”, etc.).

## Sonoanatomy of sagittal scans (first we review 2 main sagittal views)


On the upper image, we scan through the interlaminar space (lateral part of zone A). In this view, we can see the posterior complex (PC), which encompasses the dura, epidural space and LF, and the anterior complex (AC) which encompasses the ventral epidural space and vertebral body

A medial tilt to the ultrasound probe is commonly needed to obtain a better window. As we tilt medially, the lower edge of the interlaminar space becomes lower. The bony base of the SP becomes more superficial from caudad to cranial (consider the angulation of the SP).

When the interlaminar space is not visualized on US, the facet joint line may be a decent surrogate marker for the upper edge of the interlaminar space (bottom image).



What if we can not see posterior and anterior complex? In mid thorax intralaminar space is frequently obscured



It is very reassuring if we can see both the posterior and anterior complex because it signifies a large enough interspace.

What if we can not see them? Should we even try that interspace and what surrogate marker should be used?

If we can not see anterior complex in the desired space and one above or below it, we can still try that level and use surrogate markers: **facet joint line** and **cranial edge of TP**.

If we see interlaminar space, what part of it should we mark on the skin? Probably caudad for safe landing on the bone below it while aiming for its cranial portion as an end point for the needle tip.

# Possible algorithm of the “lamina palpation with the needle” (part 1 horizontal walk)

Start with a 5 mm horizontal medial step

If you are at SAP you should feel no step up. If you are **not at SAP level** then you should feel a step up. This step up is steeper if you are more caudad from ideal landing spot, and the biggest at IAP (superior articular process level)

Repeat **another one or two** (depends on how lateral was the original LS ) **5 mm medial step**.

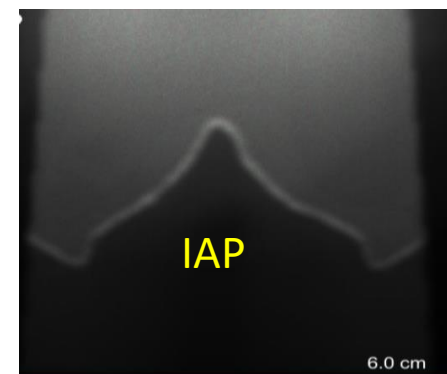
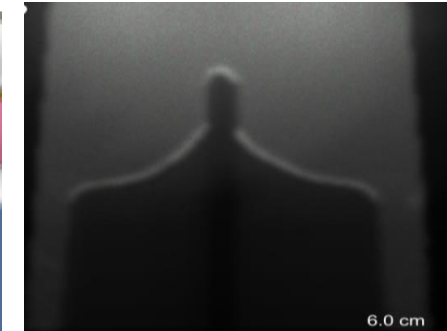
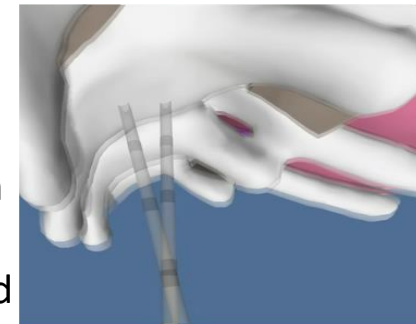

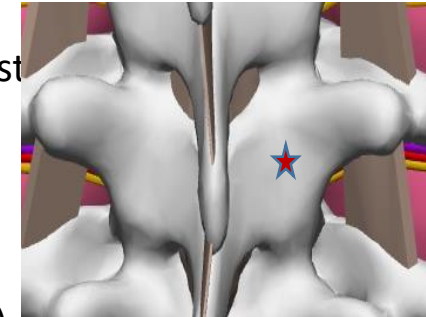

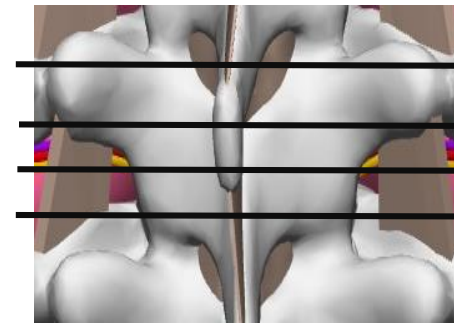
At SAP level you may “fall into ILS” after second or third step

If your initial LS was not at SAP level and was too lateral (more than 1.5 cm from true midline) you would continue climbing up during 2<sup>nd</sup> and may be even a next 3<sup>rd</sup> step.

If the original LS was too medial (less than 1 cm from midline) you may start crossing midline (feel a step down on other side past midline or start hitting/scraping side of SP above- in such case **make a step or two back and start walking up or change the entry point**).

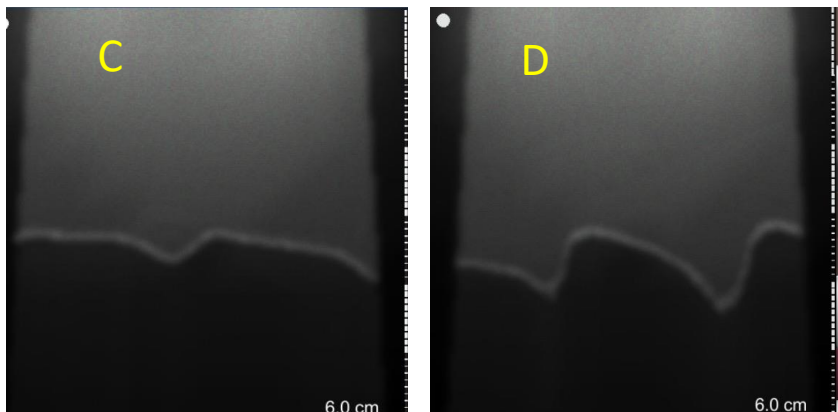
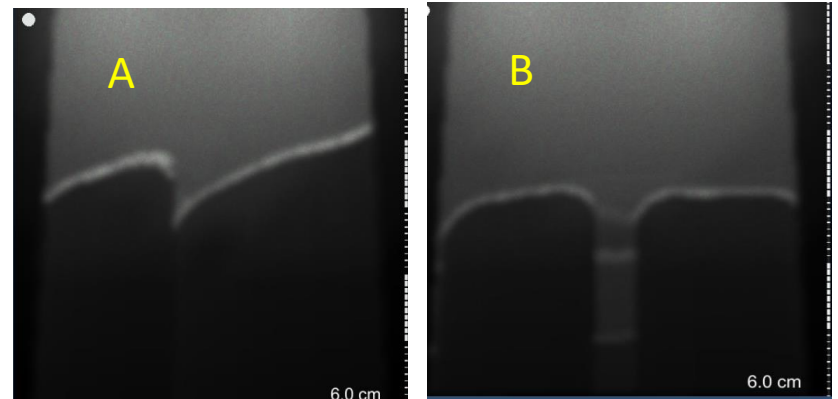
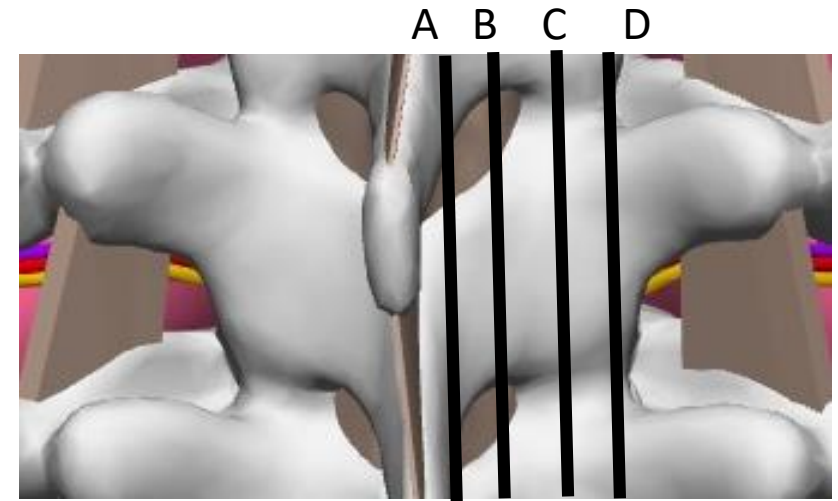
If LS was close to intended (red star) then you may feel “being too medial” on the third step and then return back and start vertical walk from a spot of your second medial step.

If unsure where the needle tip is, you can return needle back to your initial LS and **try a lateral walk; 1-2 steps laterally 5-2 mm each**. If you are at TP level you will feel a climb up towards root of TP. If you are at the level just below TP - you will feel a step down on the first step and then may get off the lamina on the second step. At IAP level and occasionally at SAP level needle may get off the lateral edge and land deeper on the head of the rib (SAP/IAP level).



# Sagittal cross sections for a more intelligent vertical walk

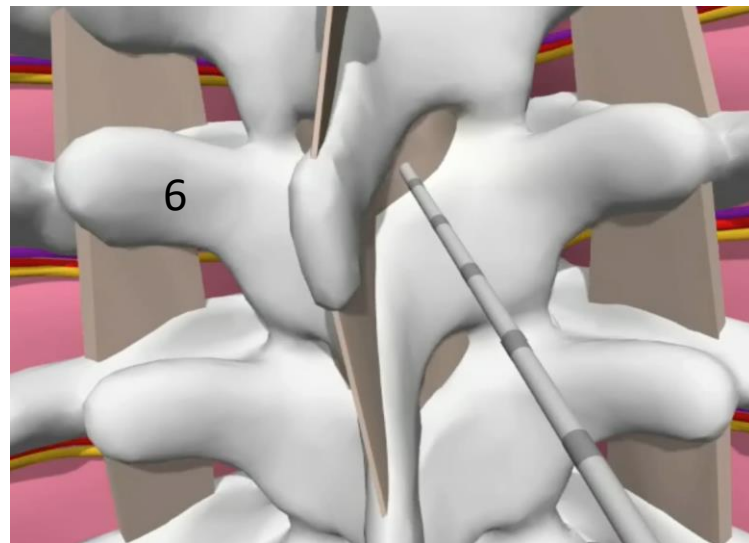
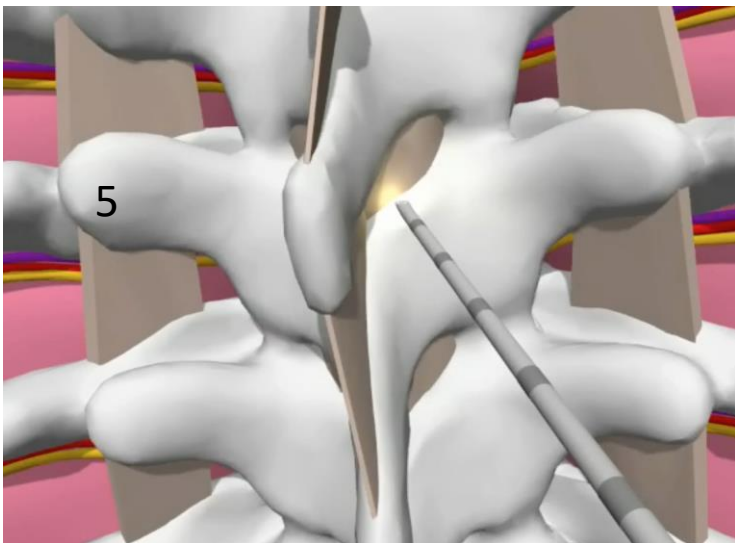
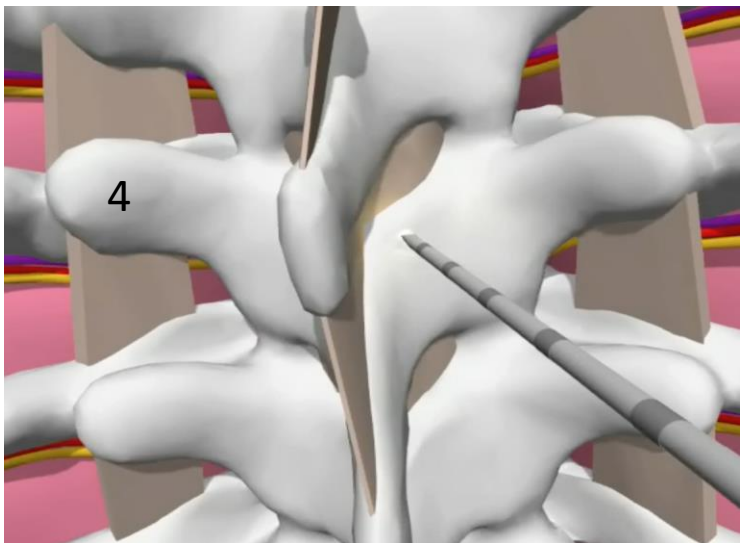
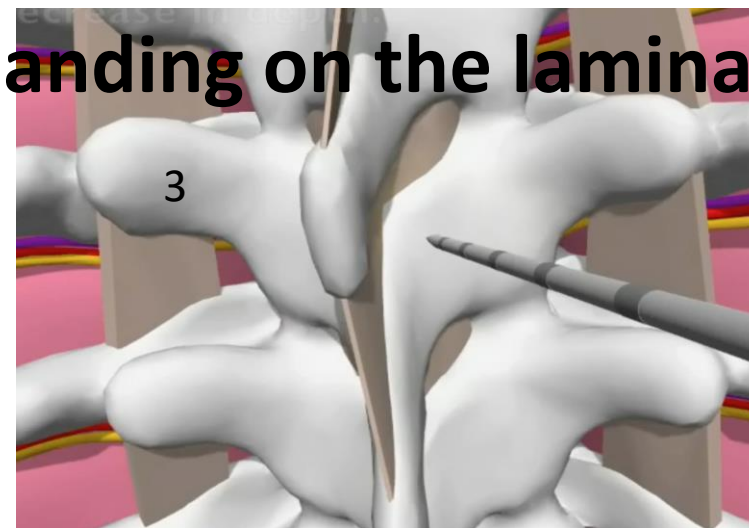
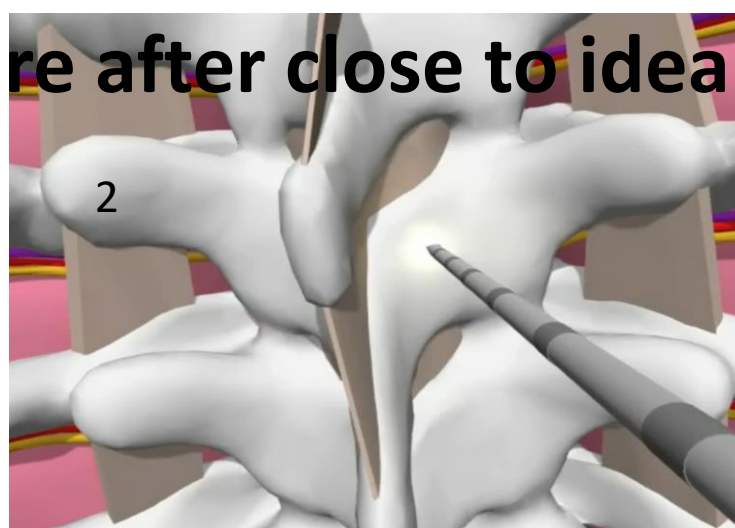
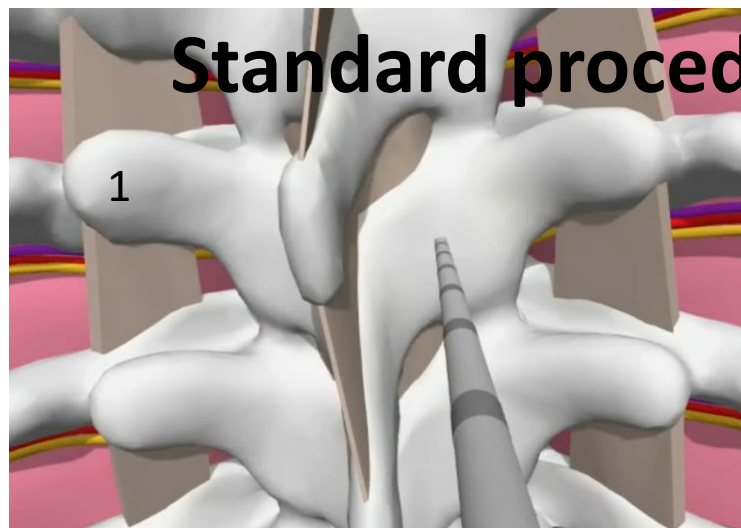
- We get some information on position of the needle during initial medial walk and then confirm it with feedback during vertical walk.
- Study the sagittal cross sections at the different distances from midline again (on the right).
- At the lines B and C, the depth of bony surface remain almost the same during vertical walk.
- There is a larger difference in the depth between the caudad (right side of the image) and cranial part of the lamina (left side of the image) as you move more lateral (line D) or medial (line A).
- Also note when the needle is too medial (line A) you may start appreciating the step down from caudad to cranial but a step up when your needle tip moves to the bony surface of vertebrae above.
- When the needle is too lateral (line D), you start feeling a step up from caudad to cranial if landing close to IAP with sudden drop down when needle reaches a facet joint line.
- **Note that if “steps” during walk are to large, you may miss important information and make a wrong conclusion.**



# Review questions

- Draw 4 typical axial cross sections:
  - 1. Over the SAP and TP
  - 2. over lower edge of TP
  - 3. below TPs but above IAPs
  - 4. over IAP and heads of the rib
- How can you get a “Namaste sign”?
- Draw 2 sagittal cross-sections over ILS and over facet joint.
- Draw another 2 sagittal cross-sections: very medial (close to midline and very lateral close to lateral edge of the lamina and root of TP). What are the biggest difference in regard of depth profile
- What is the posterior complex?
- What is the anterior complex and why is seeing it helpful?

## Standard procedure after close to ideal landing on the lamina



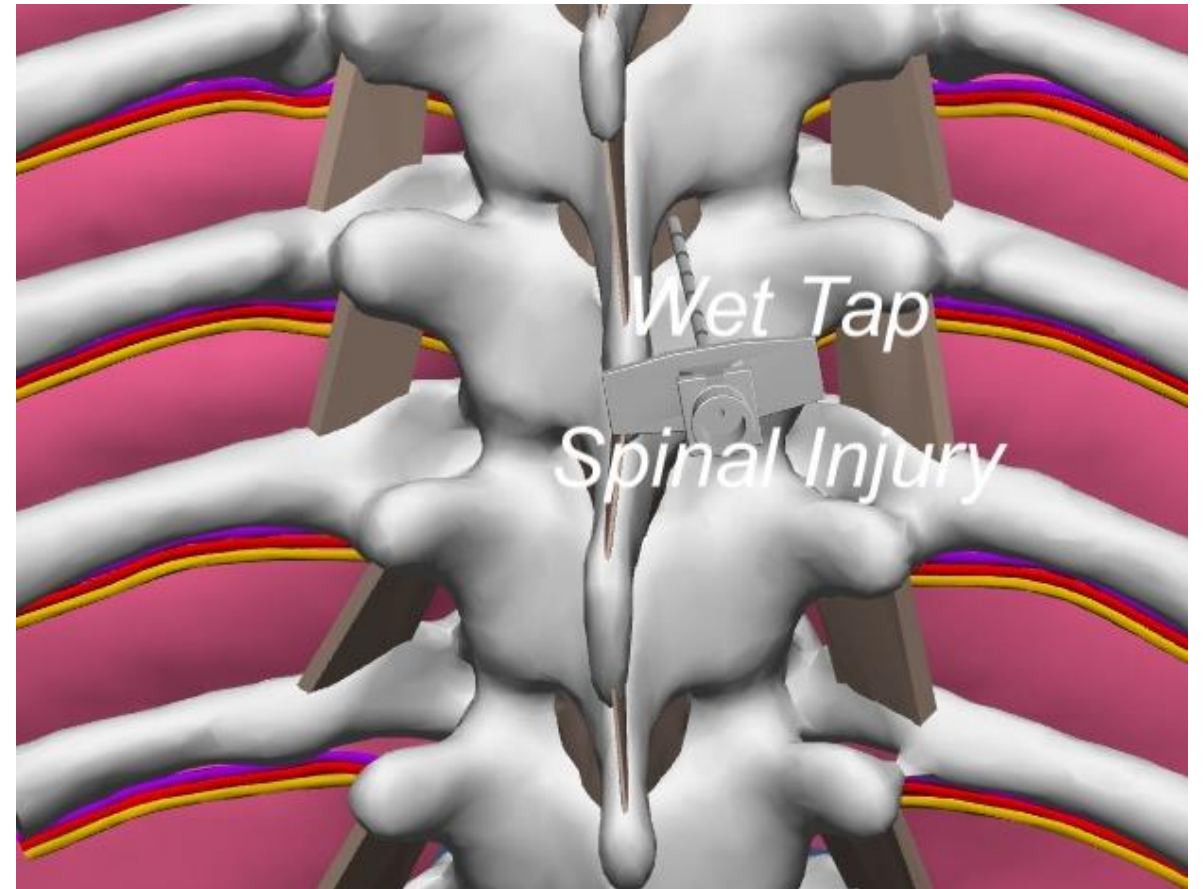
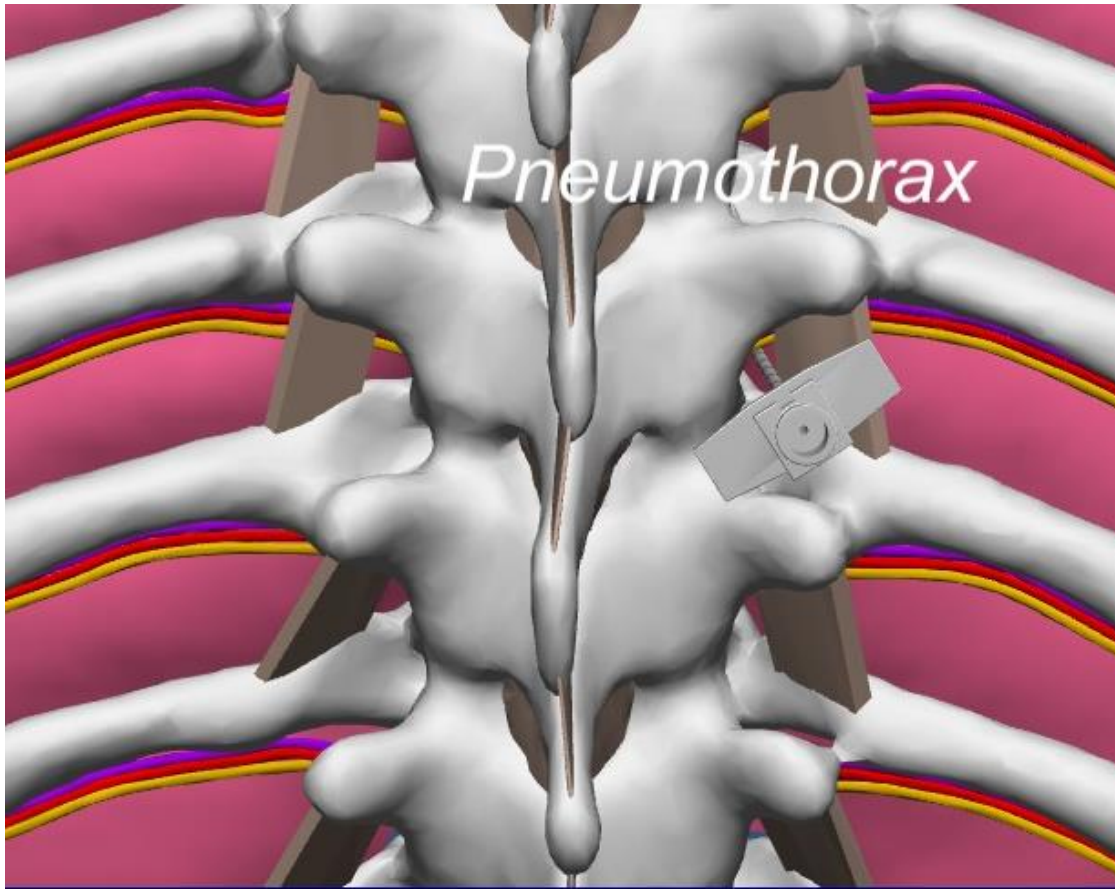
**Expected sequence of events** : after safe landing at mid lamina (1), we start a "horizontal walk " moving needle tip about 5-2 mm medially (2-first step and 3-second step). During that walk we should appreciate slight step up on more superficial base of the spinous process. Then we start walking up for another 5-8 mm with slight increase of the depth (4 and 5) until we walk off the lamina and engage in LF (6) From there we continue advancement with LOR checks until we get into epidural space close to midline.

**Since we can not see through the skin it is possible to land in a less ideal spot and have a less optimal inward and upward angulation when we are trying to find the interlaminar space.**

**Lets review a few of those cases...**

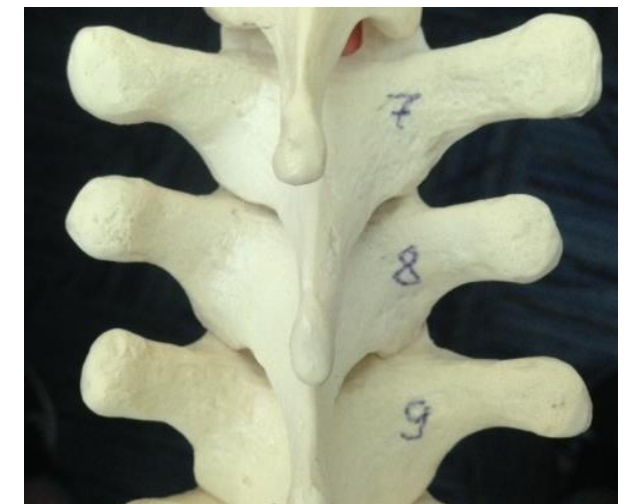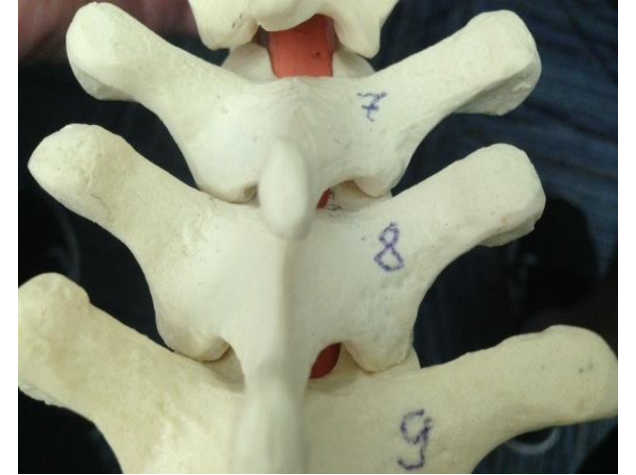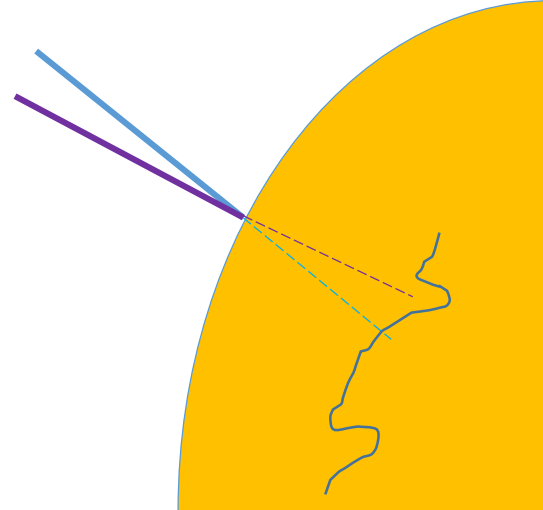


Rare but feared extreme errors during attempt of safe landing when the needle is advanced less than 1 cm or more than 2 cm from true midline while above or below the midpoint of lamina. That is why we call landing on the bone a safe landing!



Slight downward angulation of the needle could be used to decrease the chance of accidental entry into interlaminar space on the first pass while attempting landing on the lamina less than 1.5 cm lateral from midline

- Caudad angulation “closes up the intralaminar spaces” for the “eye of the needle”. It is opposite to upward angulation demonstrated during the illustration of an ideal paramedian approach.



- This may allow one to enter the skin a bit more medially (so less inward angulation is needed- so needle advancement is simpler with less chance to overshoot to other side.

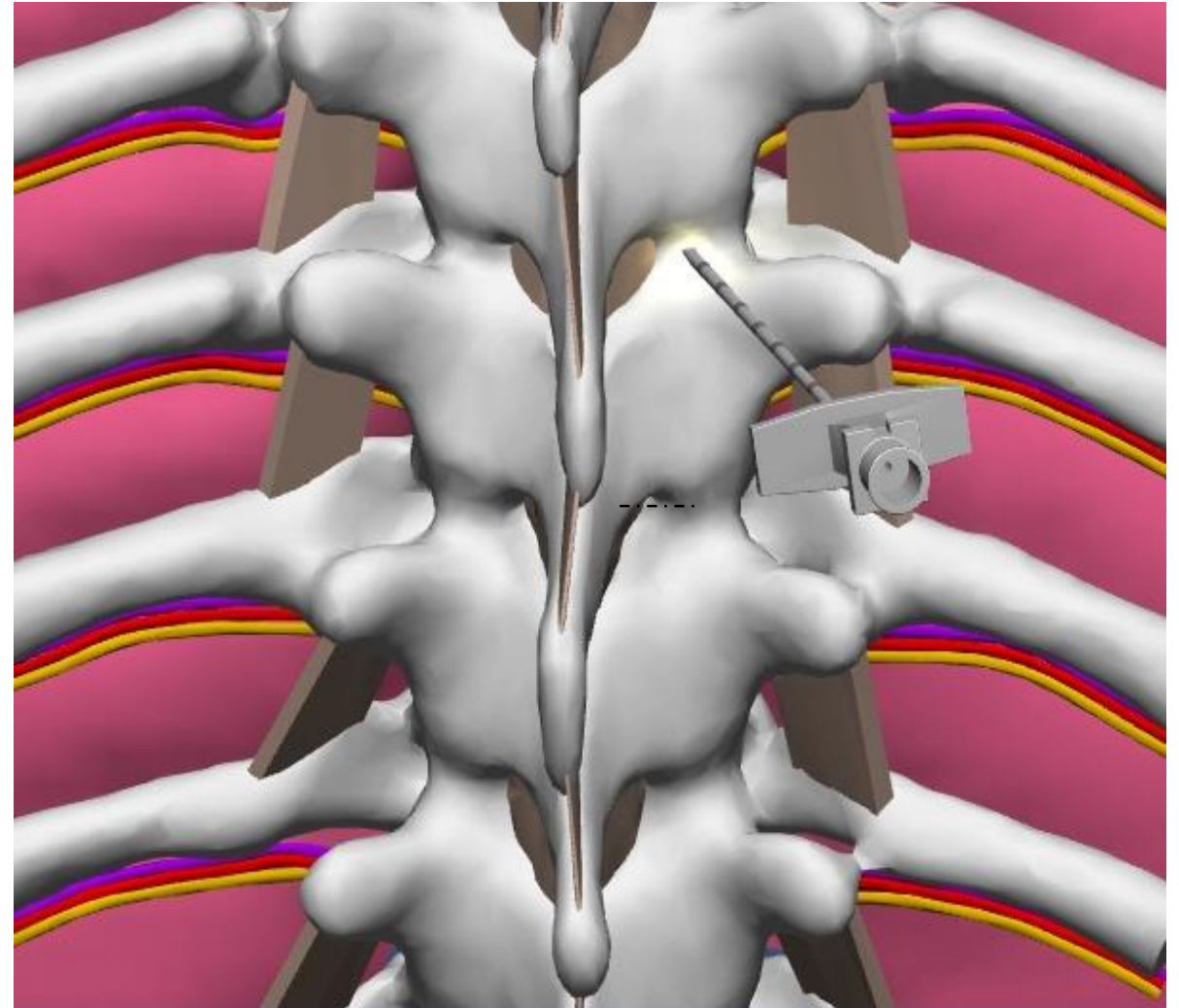
On the left: Purple line is perpendicular to skin, blue line has a slight caudad angle.  
On the right: Top spine versus bottom spine may represent the change in the view from the needle tip perspective when needle is perpendicular to skin (top) and when needle has caudad angulation (bottom). Interlaminar spaces are closed when needle is slightly angled caudad so the risk of inadvertent placement into interlaminar space is less.

## Landing on SAP instead of mid lamina

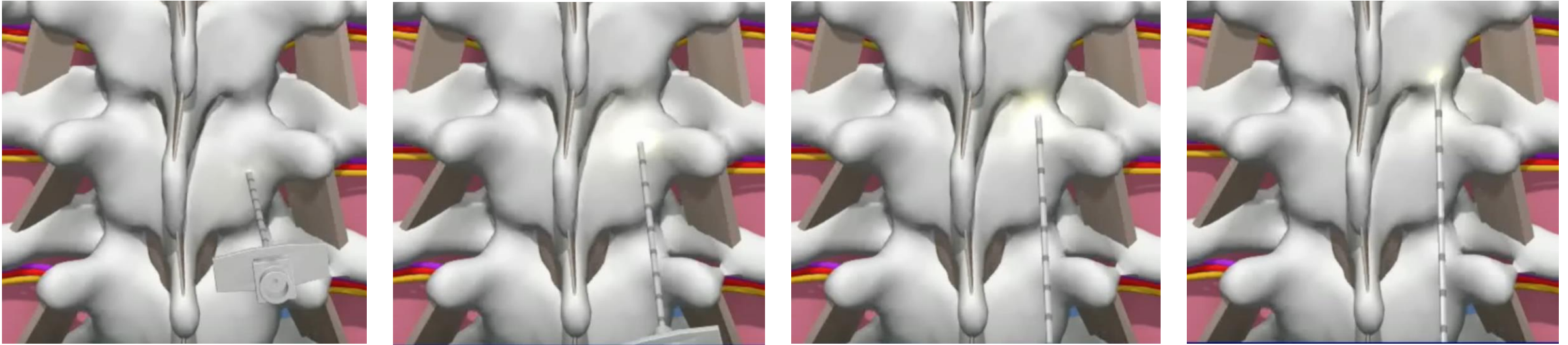
In this example, let us assume that we could not palpate the SP due to the obesity of the patient, and so, we randomly picked a spot on the skin about 1.5 cm from the midline.

Carefully advanced the needle perpendicular to all planes. Pay attention to the tactile feedback.

Once the needle contacts bone, we then do a **horizontal medial sweep**. As we walk the needle medially, we notice no step up, but instead we step down into the interlaminar space and engage in the LF.



Another example. Landing too lateral and starting vertical walk too early (staying too lateral)

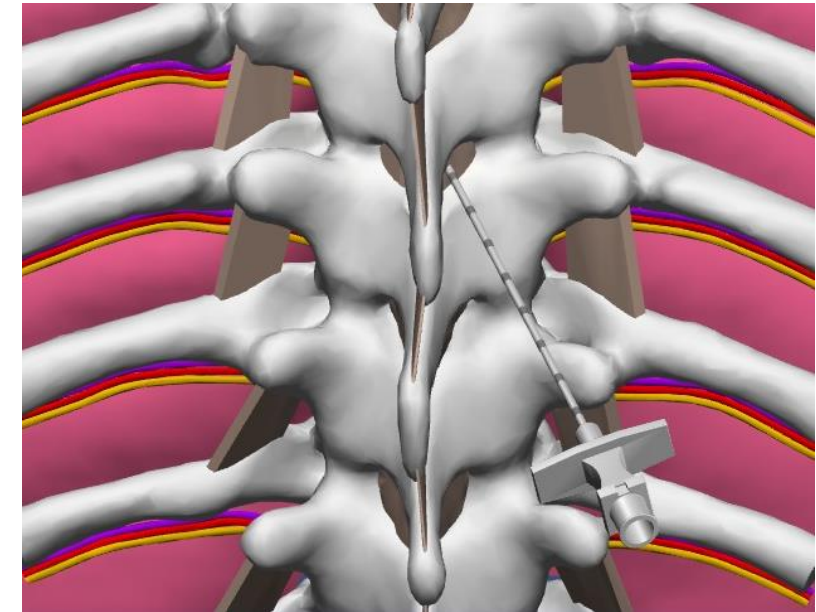
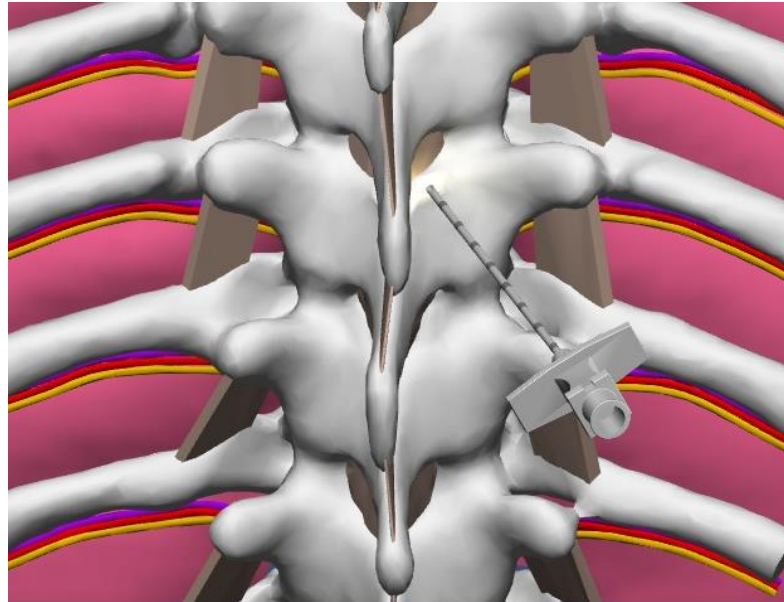
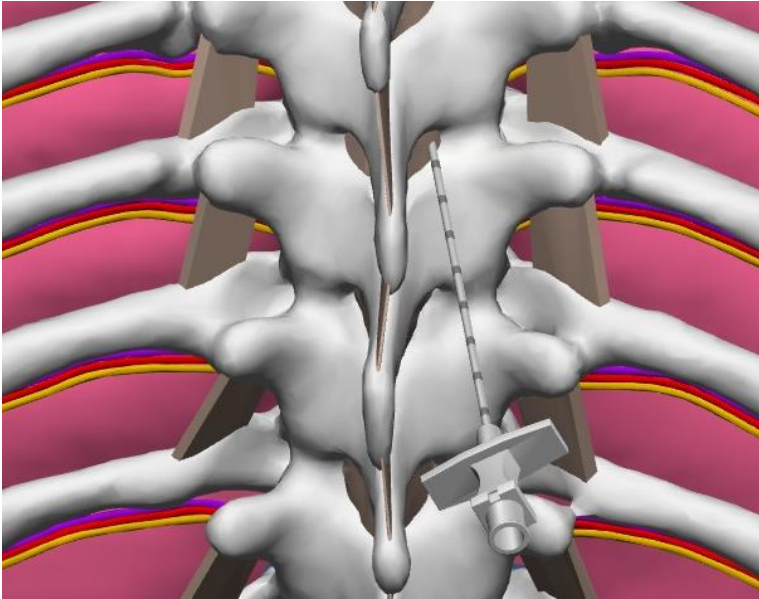


In this case we unknowingly landed too lateral and started vertical walk too early so we ended up on the “line of bones”. If you can not walk off into interlaminar space 5-15 mm after starting the “vertical walk on the lamina” consider being too lateral (occasionally you may appreciate some changes in depth of bone when you walk off into the next vertebrae).

In such cases, return back and increase the inward angulation (Extend the “medial walk” before starting vertical). Alternatively, one can reinsert needle more medially.

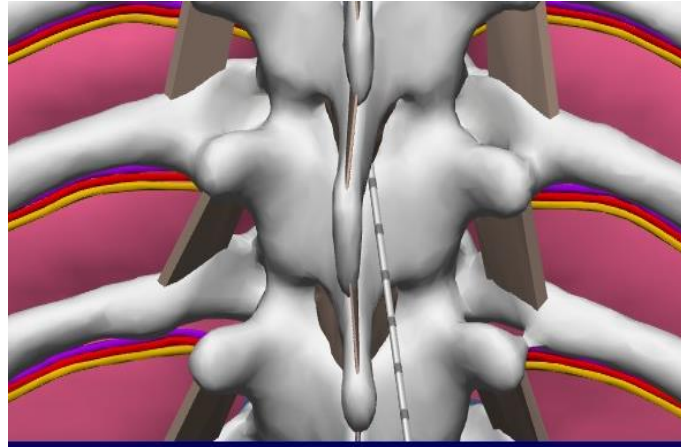
**Another example: Starting too lateral, still managing to get in the interlaminar space but too far from midline**

When the needle tip ends up too lateral in the interlaminar space after walking off the lamina, you may not feel a good engagement within ligament, or resistance (after you attach the LOR syringe). In such a case, we recommend pulling the needle back and advancing it to land on the bone in a more caudad and medial location. Then, walk off the lamina again with more medial trajectory.



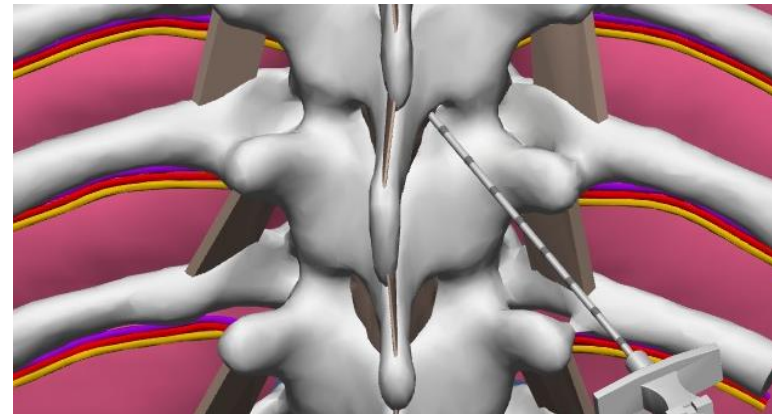
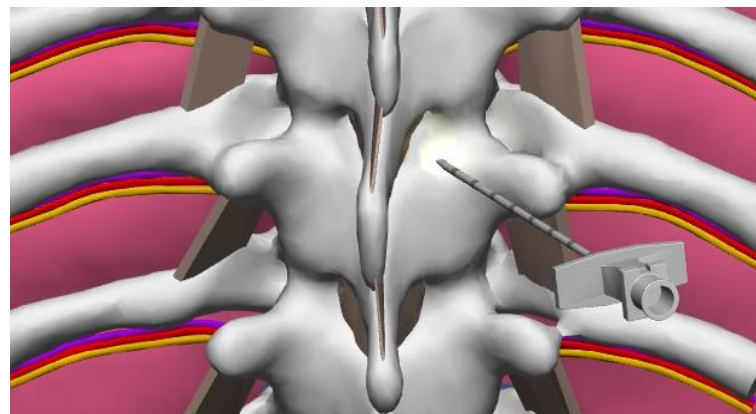
Note that the ligamentum flavum is much more robust medially and you should appreciate better engagement and LOR there.

### Another example. Landing too medially

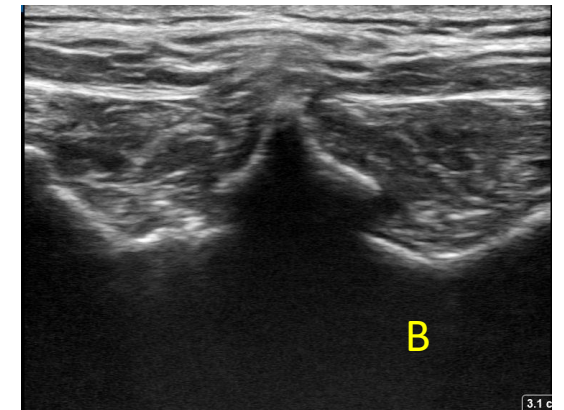
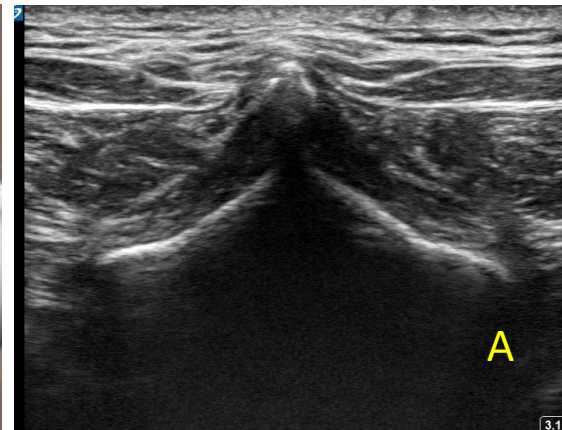
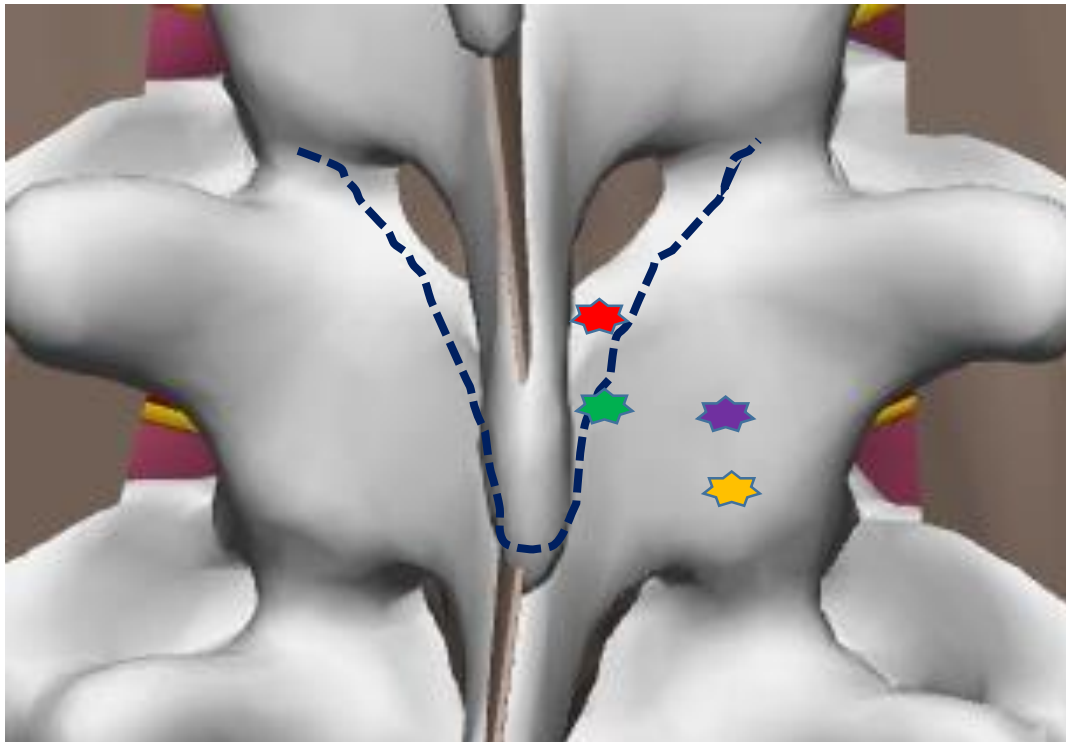


If the starting point is too medial, it may be difficult to find a bone free space between 2 SPs after first medial walk (This is the reason why we do not do midline TEC approaches at T4-T9). The solution is to choose a needle entry point that is more lateral or (probably less optimal) increase upward angulation (close to the one used with midline approach).

In the example below, landing the needle tip slightly more lateral on the lamina, and then aiming more medially allowed easier access to the epidural space. Alternatively sometimes one can try to decrease medial angulation without changing the landing spot.



## Troubleshooting problems negotiating tight spaces when spinous process base is wide (similar to landing too medial and cephalad)



When we deal with a patient who has a spinous process with a wide base we may encounter problem if we land somewhat slightly too medial and too cephalad ( that would be fine for a “skinny base spinal process”) As you can see on the illustration needle that lands perpendicular to all planes on green star will be “stuck between bones” and will not make into ILS-red star. As we showed before we need more inward and upward angulations to negotiate those tight spaces and that in turn will require to change our landing spot to more lateral and more caudad ( purple and yellow stars) US scanning prior needling can help to avoid second stick ( Transition A to B shows a transition from skinny tip of SP that gets wider at the base)

## Mini “seesaw moves” in both planes at the final steps of getting into ILS

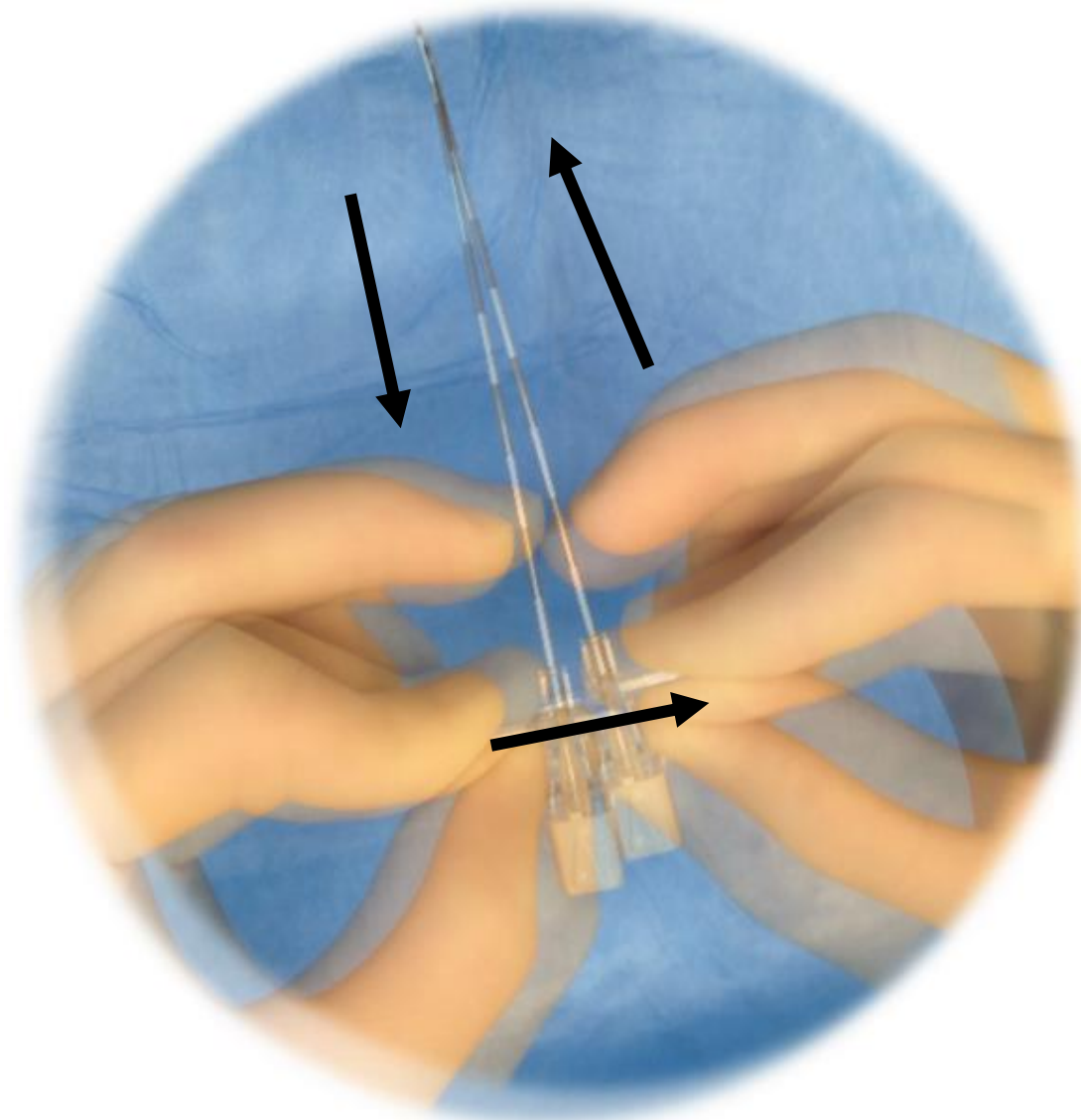
Picture shows small steps in changing inward angulation in order to find an entry into ILS

Same approach is used for upward angulation adjustment

If needle tip is deep inside the tissues, make sure you pull needle back first before adjusting the trajectory (do not bend the needle trying to muscle it in)

This small adjustment may be required during final steps of advancements.

Frequently you need it when needle unexpectedly hit the bone after what felt very “promising” in regard of needle trajectory sometimes despite feeling good engagement in ligaments



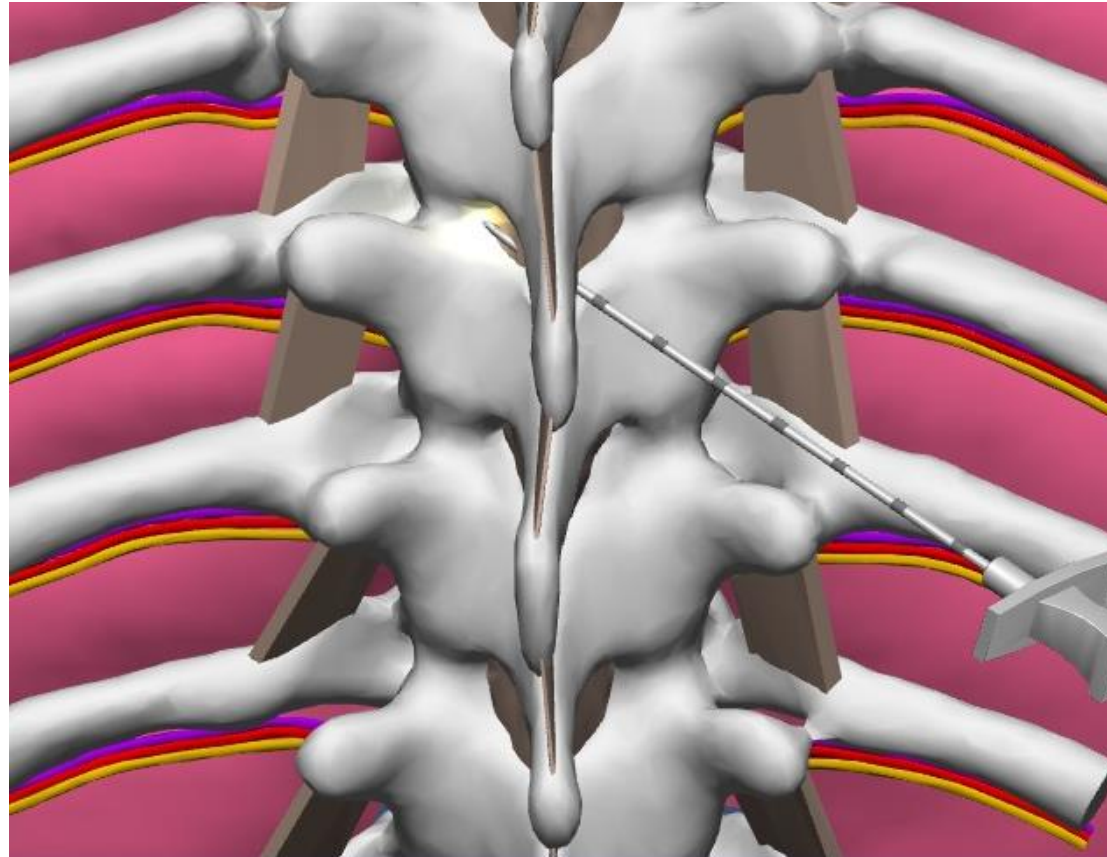


## Crossing over Midline

There is a risk of overshooting to the opposite side especially when one 1) lands on the lamina too lateral, 2) the epidural space is too deep 3) uses excessive inward angulation, 4) has poor appreciation of true midline.

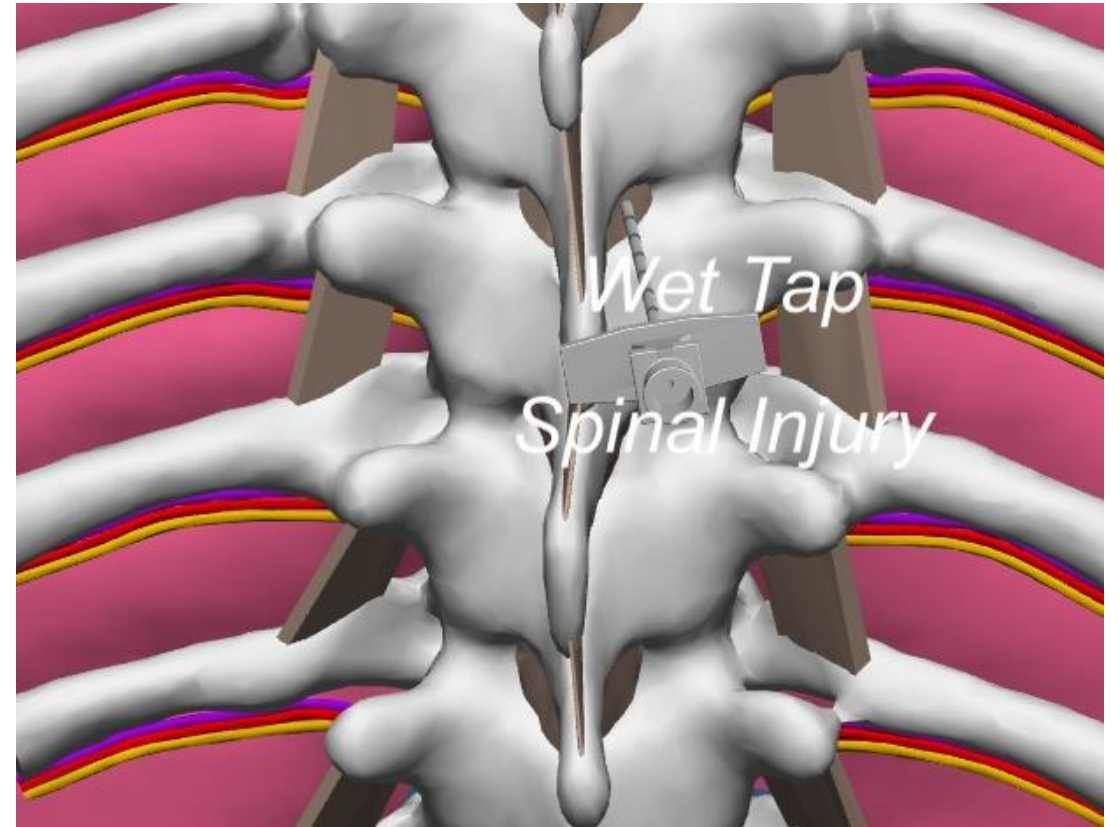
Be aware: in some cases (see illustration) you may have a LOR even if the needle tip is outside the epidural space. This will be a false LOR because you will end up in a fat pocket on the opposite side.

**Always be mindful of where the midline is and where the needle tip is in relation to a midline.**



# Warning!

- If you feel that you walked off the lamina and engaged in the LF, but do not have a LOR after advancing the needle more than 5-7 mm, consider that there is a tissue plug in the needle.
- Stop and reinsert the Tuohy stylet and recheck for a LOR before continuing to advance the needle.
- Another case when you do not experience a LOR as expected within 5mm after engagement with LF happens when you cross over the midline.

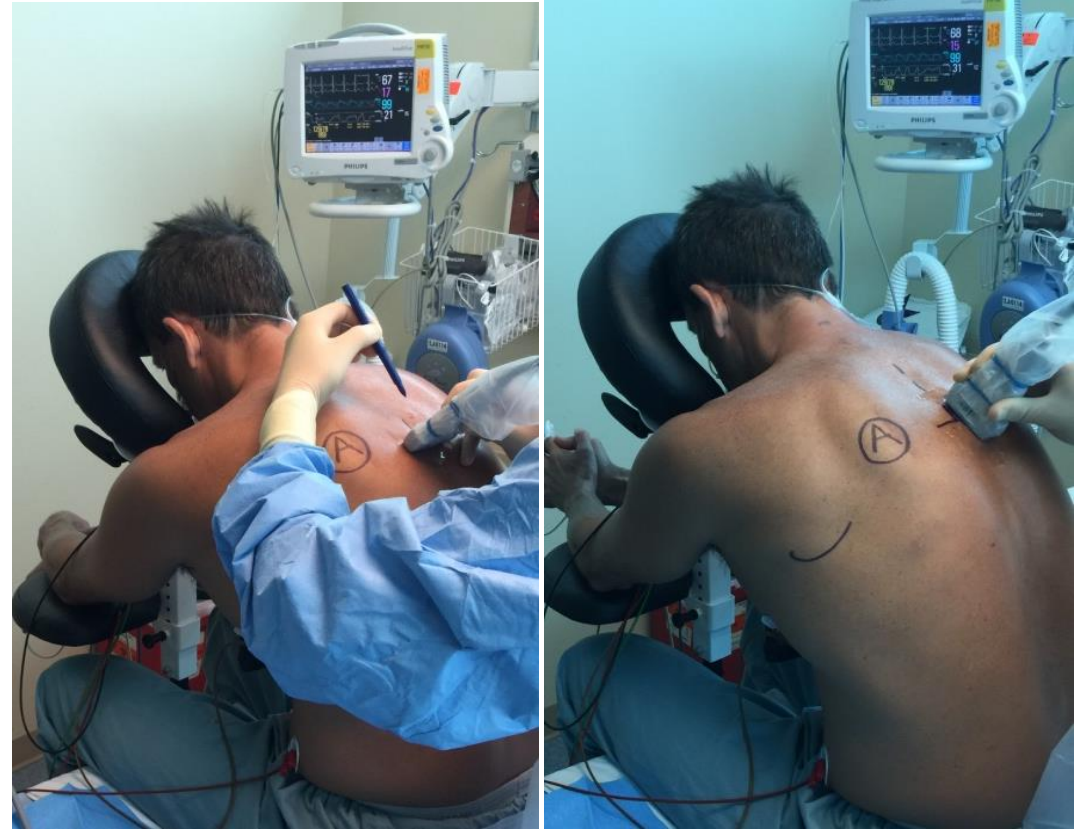

# Review questions

- Explain how some caudad angulation may decrease a chance of accidental placement of the needle into ILS during the “Safe Landing” attempt.
- What are the most feared complications during “safe landing attempt”? When do they occur?
- Describe how the “lamina walk” after landing on SAP feels different compared to “lamina walk” after landing on mid lamina.
- What should you do if after walking off the lamina into ILS you do not feel resistance and engagement?
- What do you do if you cannot find the ILS despite about 15 mm of vertical walk (the resulting upward angle is way more than 60 degree)?
- Name the risk factors for crossing over the midline?
- What is a safe distance of needle advancement after getting into ILS and engagement with LF before you decide to reinsert the stylet into the needle if there is still no LOR?

# Consider use of US to assist with epidural placement

- This may give you a better chance to land the needle in a more ideal spot on the lamina and have a better idea about required inward and upward angulation.



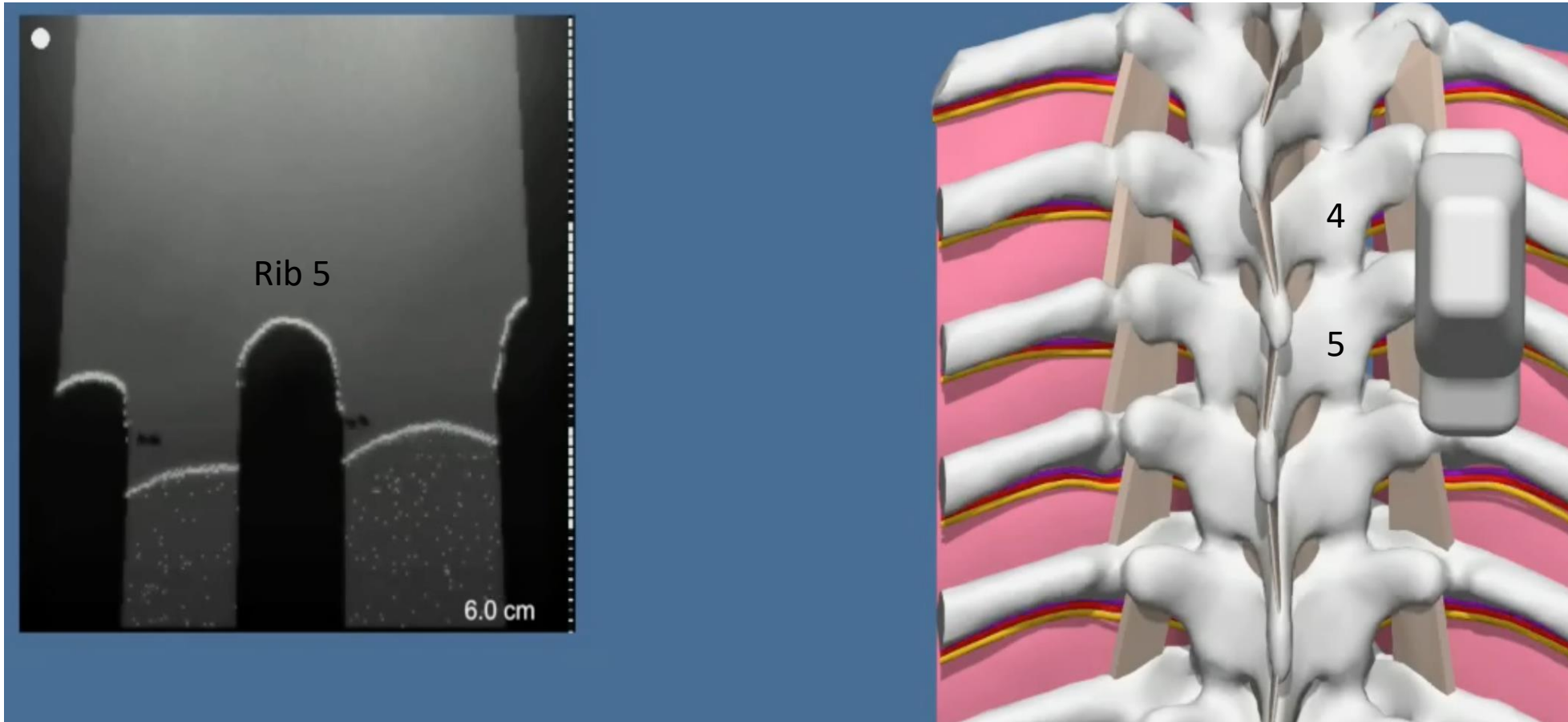
# Use of US for placement of thoracic epidurals

- We do not use a live US guided technique (could be more technically difficult and the US gel could be irritating to the meninges if it is inadvertently introduced into epidural space).
- We use US assisted TEC placement (conventional paramedian approach with benefits of “peeking through the skin” and marking/measuring with US before prepping the sterile field).
- US may help:
  - To determine the required level more precisely, compared to surface landmarks (counting ribs with US)
  - To find the widest interlaminar space
  - To adjust patient position to make ILS bigger
  - To find the optimal landing spot on lamina
  - To mark skin projection of the interlaminar space and estimate depth to it from entry point
- US depth is usually slightly less than needle depth (depends on degree of tissue compression, and alignment of US and needle trajectories). The basics of marking and measuring was covered in TPVB lecture.
- For skinny patients one can use a linear high frequency probe, as a curved low frequency probe is better for bigger patients.

# Review questions

- Name 5 potential advantages of using US for thoracic epidural.
- What US probes are used and in what situations?
- Why don't most people use US live for epidural placement?
- How is the US measured depth of the structure different compared to the so called "needle depth" to the structure and why?

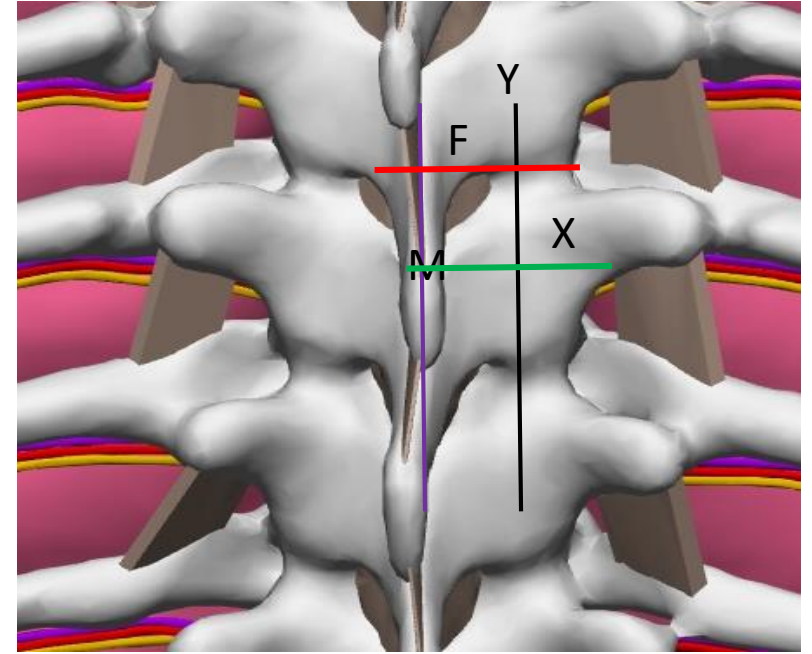
**Using rib counting to determine the level of the block.  
For example: find and mark rib 5 for T4/5 epidural**



(if need to do a T7/8 epidural find and mark rib #8)

# Steps of US assisted marking and measuring for paramedian epidural (consider T5/6 level) Details are on the following slides

- Marking the correct level by utilizing US rib count: US transducer sagittal, count from the top or the bottom rib and find the same rib as a lower vertebrae: for T5/6 epidural find rib 6 and mark it.
- While the transducer is still sagittal, a) outline the caudad edge of the **root of TP6** after sliding the probe medially from rib. The level of the caudad edge of TP is one of the surrogate markers for the **horizontal level for future safe landing: line X**. Alternatively to mark line X, one may ignore TP and continue sliding transducer medially until lamina and mark the midpoint between facet joints above (5/6) and below (6/7)-**line X**.
- Do an axial scan at the line X and find the midline of the vertebrae 6 (may need to tilt the probe down and focus on base of SP6 and not tip of SP5). After marking the midline(**line M**), draw a line parallel to midline at about 1-1.5 cm lateral to it: **Line Y** (1 cm is probably better if base of TP is not too wide-that is seen on US).
- Do a sagittal scan over 5/6 facet joint (should be about 1 -1.5 cm from midline and about 1-1.5 cm above the level of line X ) and mark the projection of the joint line on skin as a good surrogate marker of the interlaminar space level (**Line F**).
- Connect both marks (line M and line F) as a skin projection of the target (interlaminar space).
- Needle entry point is at **intersection of line X and line Y**.
- Place US over the needle entry point and assess the depth to bone and proximity of ILS (may need to tilt probe medially to visualize ILS) Estimate (eye ball) expected depth to ILS.
- One can use one “diagonal walk” for US assisted technique or usual combo of medial and then vertical walk. See the entire procedure on video.



X-line –horizontal level for Safe Landing (derived from the level of caudad edge of TP or midpoint between adjacent facet joints)

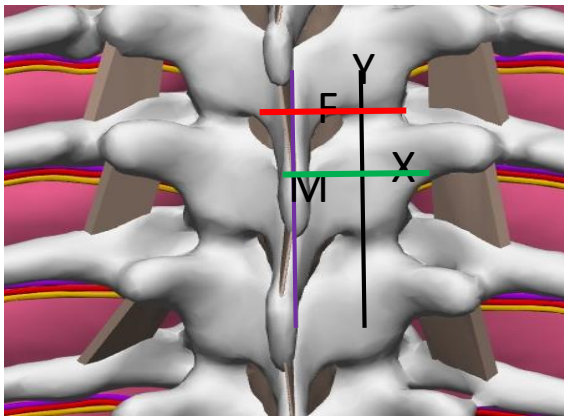
F-line facet joint line

M-line –midline, Y-line -line parallel to M-line 1-1.5 cm lateral to it.

XY intersection is a skin projection for a safe landing.

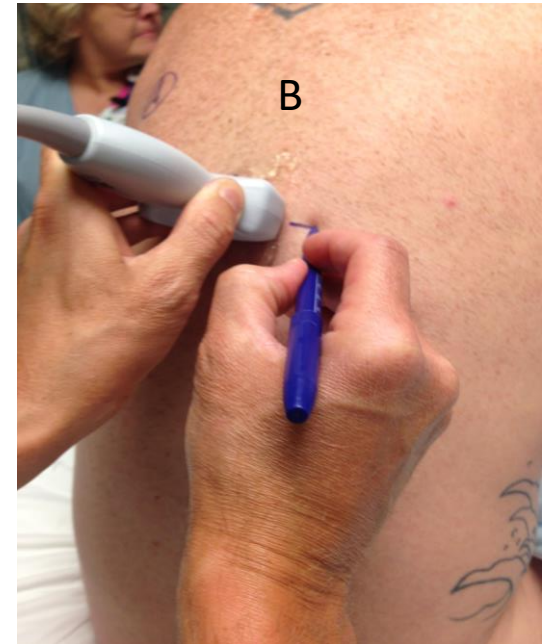
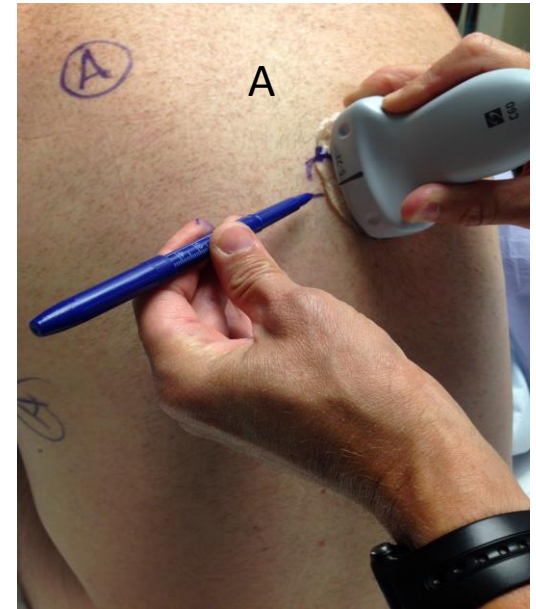
FM intersection is a projection of the target point



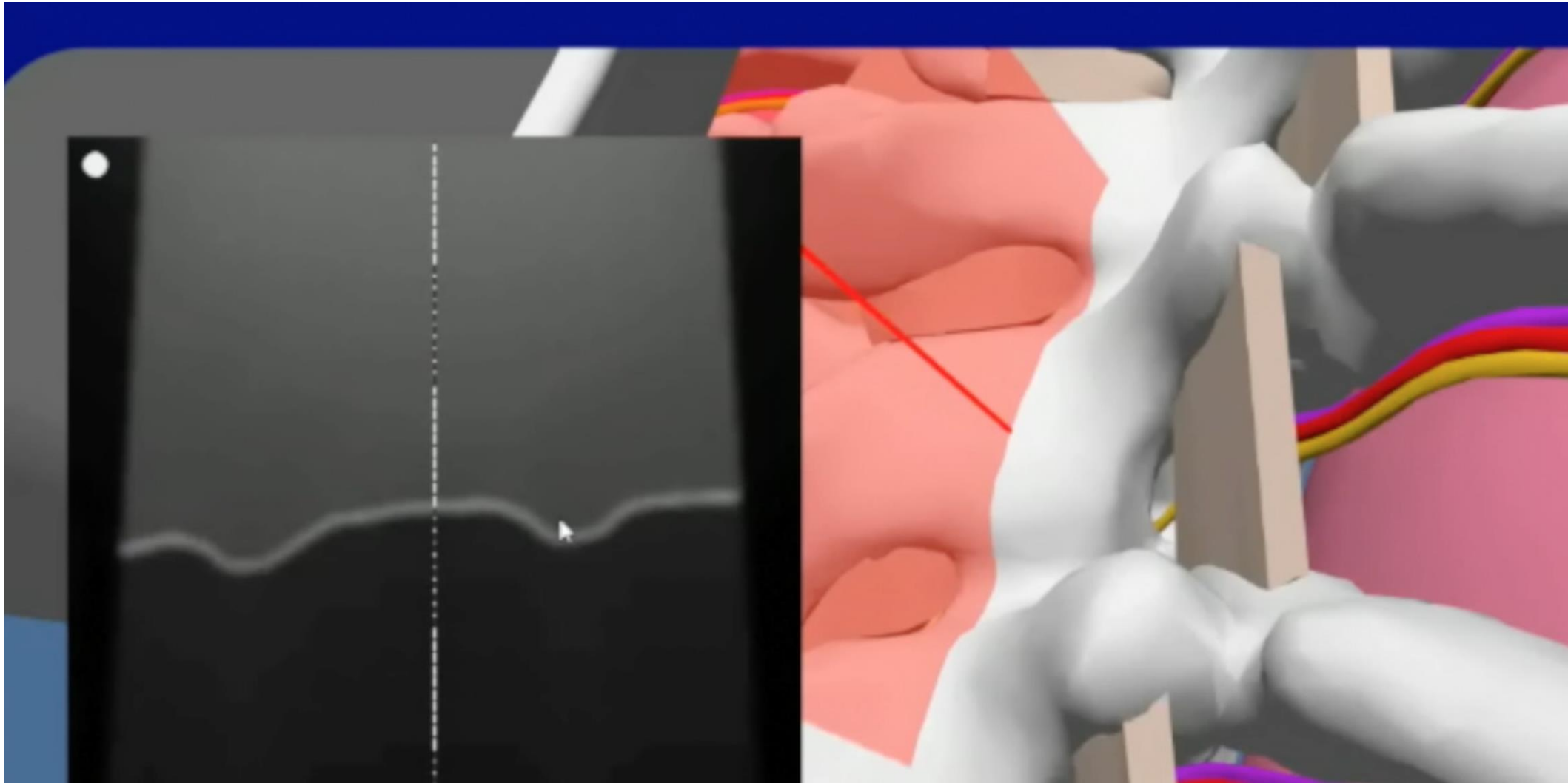


## 3 ways of marking line X

- US probe is sagittal-A (mark the middle of the longest side of the probe)
  - ❑ Using a midpoint between adjacent facet joints as a surrogate marker for the horizontal level for SL
  - ❑ Using the level of the caudad part of root of TP (it may be helpful to go slightly lower in upper thorax where TP are pointed up).
- US probe is axial-B (mark the middle of the shortest side of the probe)
  - ❑ Going about 1 cm caudad from the mark when we marked the probe position while obtaining the view close enough to “home image”.

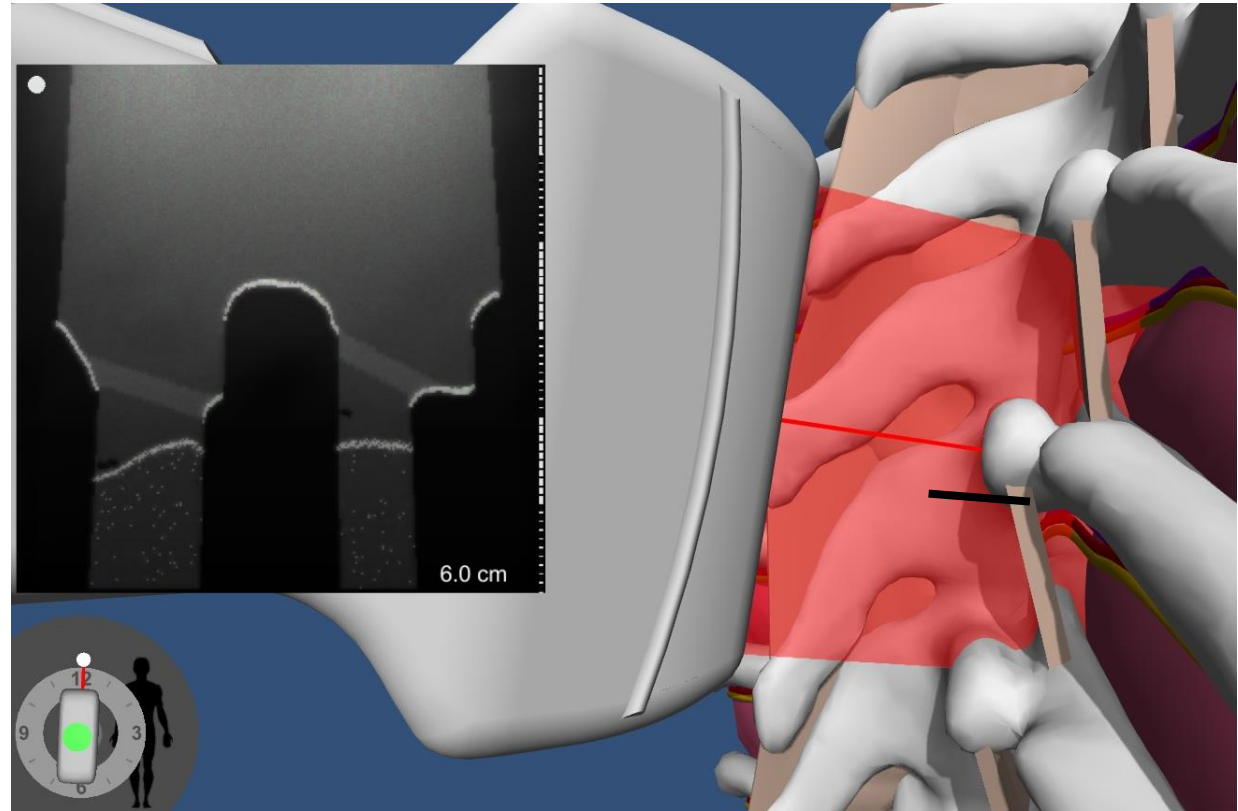
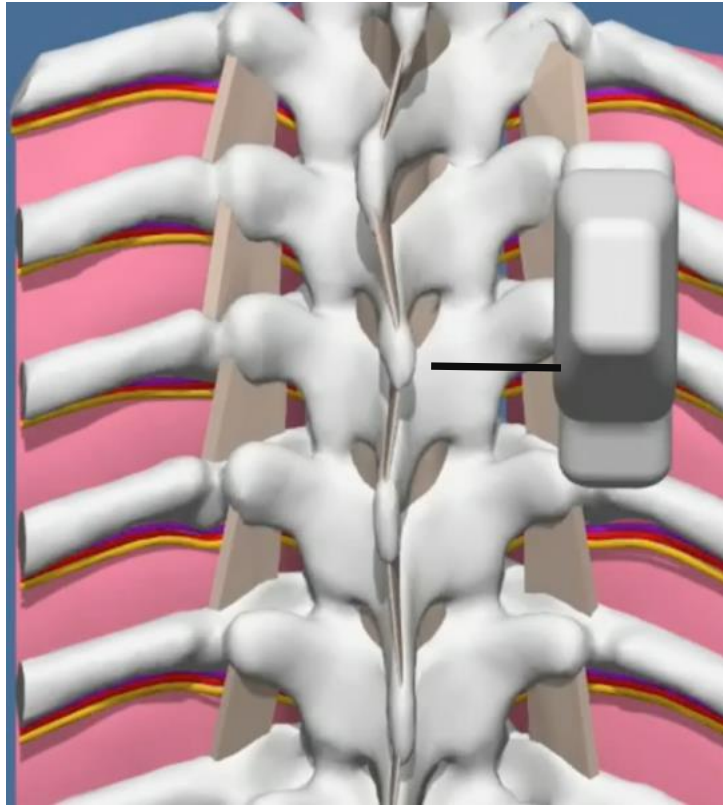


Using a midpoint between adjacent facet joints as a surrogate marker for the horizontal level for SL




This could be a preferred technique for a skinny patient. Just place transducer medial to SP (slight medial tilt needed) and slide it cranially or caudad to place the target in the middle of the screen) Estimate the depth and the distance to ILS. It is reassuring to see wide open ILS when probe is tilted ore medially. One may slide probe up and outline the level of ILS at once during this step.

The caudad portion of the root of TP5 is an excellent surrogate marker for the horizontal level of Safe Landing spot (it may be helpful to go slightly lower in upper thorax where TP are pointed up).



- After locating the correct rib, we recommend sliding the probe medially to visualize the transverse process.
- Mark the skin projection of the caudad edge as a surrogate marker of the horizontal level for safe landing. Marking another line 1-1.5 cm from midline on that line(see next) will produce a good skin mark for a safe landing


## Marking midline with US when palpation is difficult



Place the probe axially at the level of the caudad edge of the root of TP and **slightly tilt it down**. Do not use tip of SP of vertebrae above to determine the midline (SPs tips are commonly deviated, use base of SP of vertebrae below. Also note the depth of the lamina about 1-1.5 cm from midline. Here is slightly less than 4 cm).

BTW in this case tip of SP is deviated to the left so it may be a bit easier to access interlaminar space from the right if we do epidural not for a thoracotomy (for thoracotomy we try to place epidural from contralateral side to keep the dressing away from surgical field)

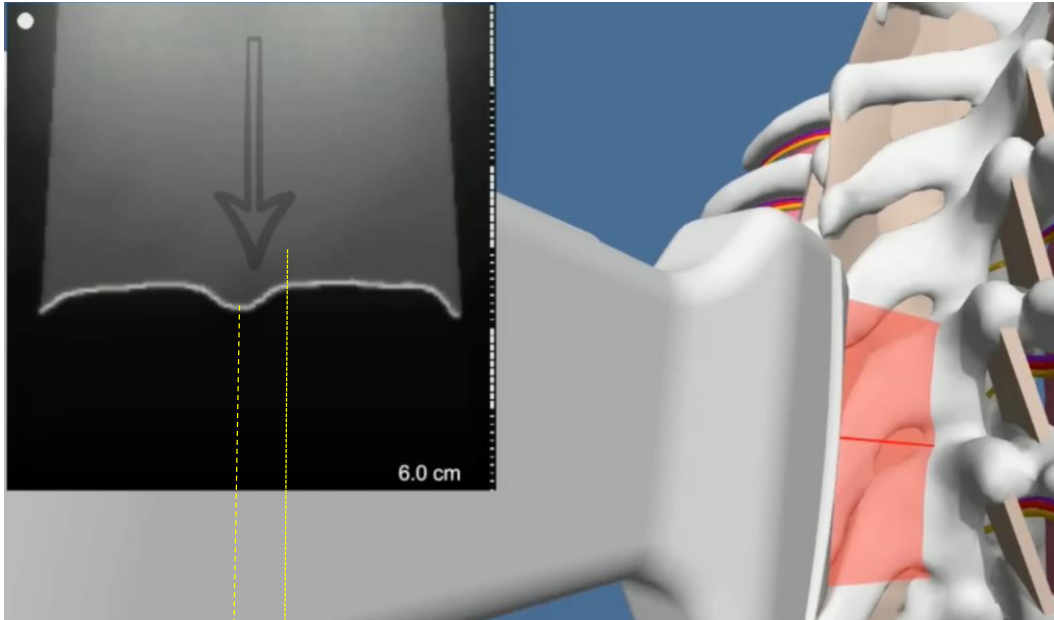
# Using facet joint line at required block level to outline the horizontal line that works as a surrogate marker for the targeted interlaminar space



Place the probe sagittal about 1 cm from midline with its middle about 1-1.5 cm above the level you recently outlined for safe landing (caudad edge of root of TP) When visualizing a facet joint line adjust the probe up and down until the joint line is in the middle of the screen.

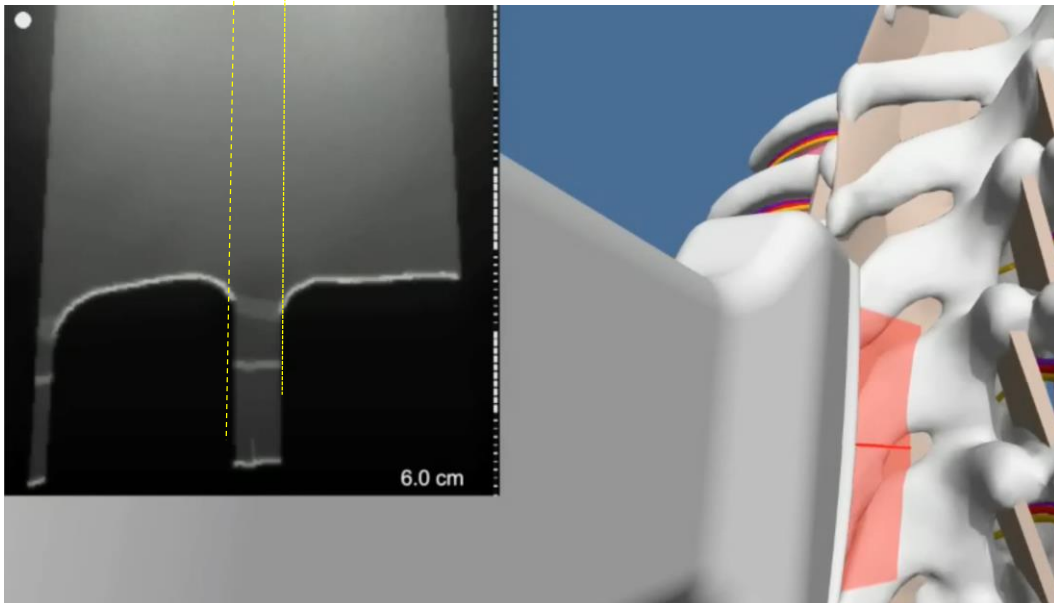
Facet line is commonly easier to visualize than an actual interlaminar space and it works good enough as a marker for horizontal level of the target. Be aware the most caudad edge of interlaminar space is commonly about 1 cm below the joint line. One more time, estimate the depth to the lamina (safe landing depth, here it is about 4 cm on US and probably 4.5 cm for a needle contact).

## US image of facet joint line versus ILS? Relationship and differentiation



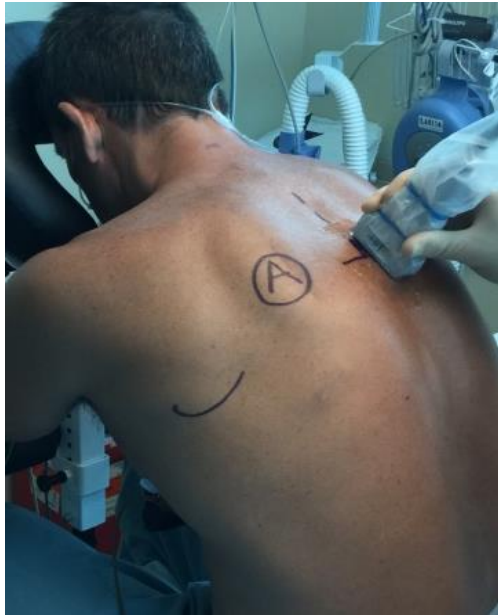One can do a quick medial tilt of the probe and see if it is possible to visualize the interlaminar space. Note how far the most caudad edge of interlaminar space is from the facet joint line. Here it is almost 1 cm below it. Note the great view of interlaminar space on the bottom picture in this particular case/level with anterior (vertebral body) and posterior (LF, dura and epidural space) complexes well seen.

It is helpful to try to adjust patient position to open that space up (more flexion) if view is less favorable.

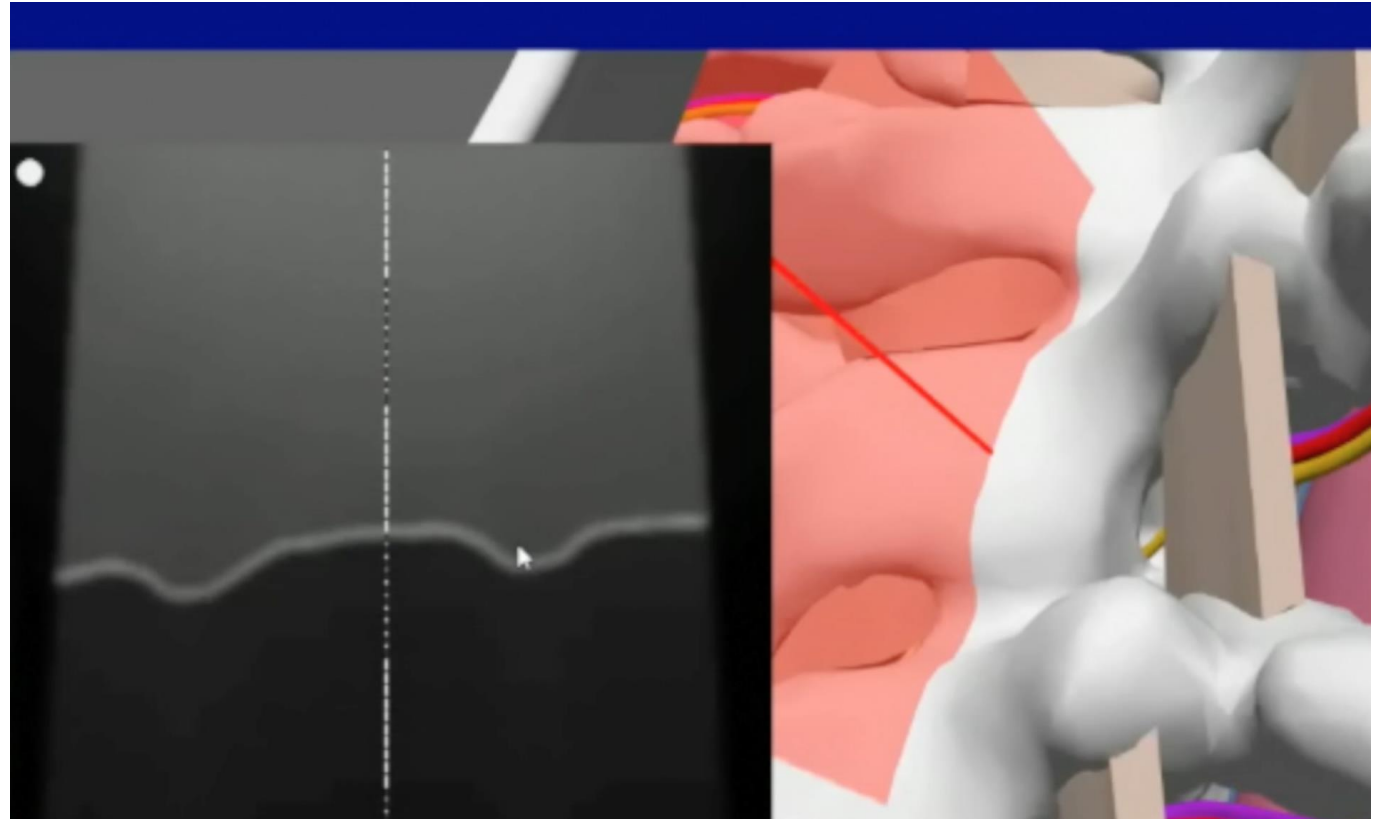


Occasionally if it is difficult to “open up” the required space but adjacent space is wide open, then it is reasonable to consider doing epidural at the level with more open interlaminar space. We commonly still can get into ILS despite the fact that we can not see both anterior and posterior complexes. It is may be wise to consider the space with wider ILS on US if we have difficulties with the initial placement.

Place US probe sagittal on marked future needle entry point and assess the accuracy of the mark and depth



After we place the probe on the marked entry spot everything looks correct: the depth to LS is about 3 cm (it will be slightly more for a needle) and we should walk off into ILS within about 15 mm.



# Order of steps for US assisted epidural

It is not important what line is marked first or second but these are some recommendations

**Skinny patients (easily seen or palpable landmarks: midline, SPs)**

First mark the correct level by counting ribs with US (alternatively count SPs from C7 down, remember when counting SP- mark the one above the required ILS and the one below: for T5/6: SP 5 and rib 6)

If midline is clear on the surface, go straight to marking the mid lamina at the correct level (mid point between facet joints immediately lateral to marked SP).

While marking, also note the depth to mid lamina, then slide probe up and mark facet joint line at the interspace level.

One would insert the needle 1-1.5 cm from midline at the level of mid lamina and guide the needle towards midline at the level of facet joint above .

Before needling, place US probe over future entry point for one more confirmation and depth measurement.



# Order of steps for US assisted epidural

**If landmarks are obscured to eye or palpation (high BMI etc)**

Consider using a curved low frequency probe. After marking the correct rib (probe sagittal), mark the midline-A (probe axial) slightly below the level of marked rib.

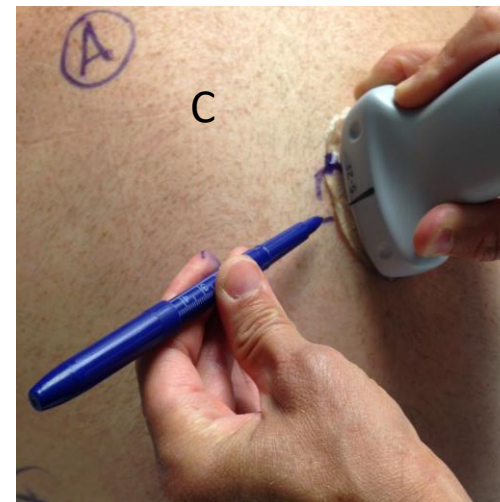
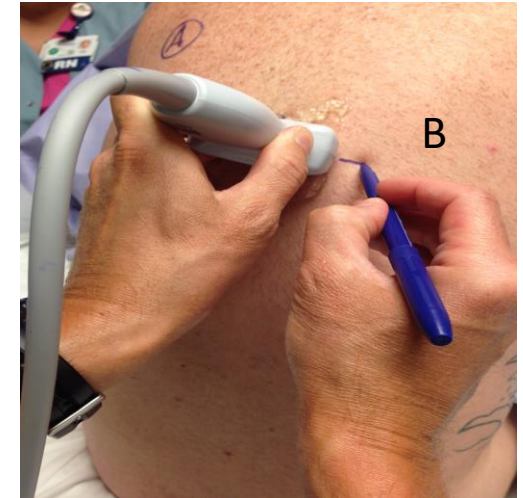
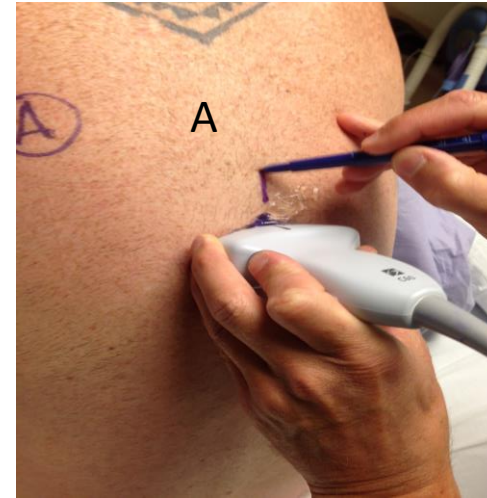
While marking midline, try to keep probe perpendicular to all planes at the level of TPs and then also mark the level of the probe (lateral to the probe-B). Before taking probe off the skin note lamina depth.

When probe is off the skin mark vertical line (line Y) 1-1.5 cm from previously marked midline.

Slightly lower than TP level (mark that you made on the side of the probe) is a level of mid lamina or X-line/level.

If lamina is visible in sagittal view than mark mid lamina and facet joint line next-C. See if you can visualize ILS and see posterior complex.

AS you see here we try to mark midlamina level based on both axial and sagittal scans due to risk of inadvertently rocking curved probe and making wrong if only sagittal scan is utilized.



# Review questions

- When doing T7/8 epidural what rib should you mark with US?
- When marking midline with US at the level of marked rib should you focus on SP tip of T7 or SP base/lamina of T8?
- What is line X? Describe 3 ways of marking line X.
- How do we mark line Y?
- What is line F? How it is different from mid level of ILS?
- Where should we insert the needle and what is the direction of the needle?
- What is the purpose of putting US on the marked point of future needle entry? How do you place it?
- How and why do we mark the level of TP when the patient is obese?
- If you can not visualize the anterior complex at the required level but it is well seen at the adjacent level what would you do?